



ACADEMY
OF IMMUNOHISTOCHEMISTRY

Diagnostic Immunohistochemistry for Pathologists

13th April 2018, Cadiz, Spain

Most common interpretation pitfalls in Immunohistochemistry



Jan Klos MD

**Stavanger University Hospital
Stavanger, Norway**

Conflict of interests

NONE

Interpretation pitfalls

Not as common as technical?



- Use of inadequate antibody panel
- Unexpected antigen expression
- Unexpected lack of antigen
- Unknown cross reactivity of used antibodies
- Unidentified technical error
- Not enough thorough microscopic examination
- ...

Adequate tissue block

Adequate antibody panel

Adequate antibody
clone

Adequate staining of
internal/external controls

A aberrant reactivity

Structures stained

Pattern of staining

Intensity of staining

Number
of stained cells

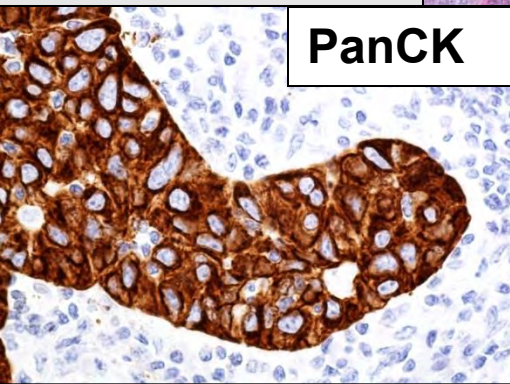
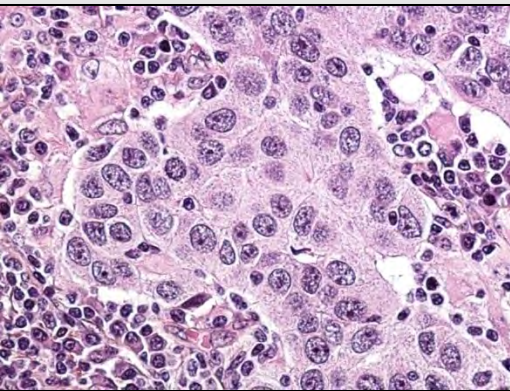
Since optimal interpretation of immunohistochemical tests requires careful control of a number of different variables the **5A-SPIN** algorithm may serve as a check list



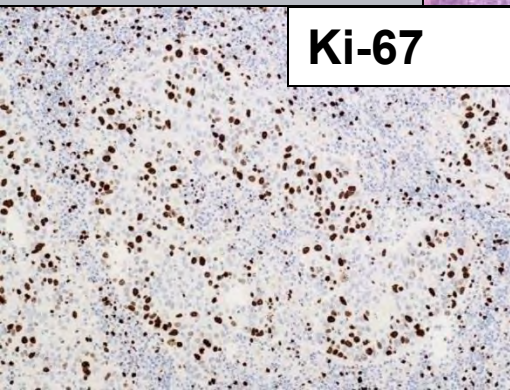
Adequate tissue block

- **Select the block with best preserved morphology indicating the best fixation**
- **Try to avoid necrotic/degenerated areas**
- **Try to include normal tissues which may serve as internal positive control**

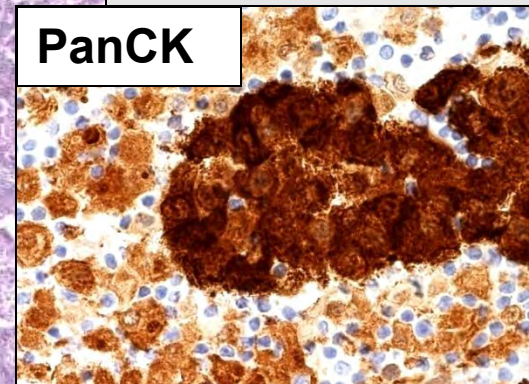
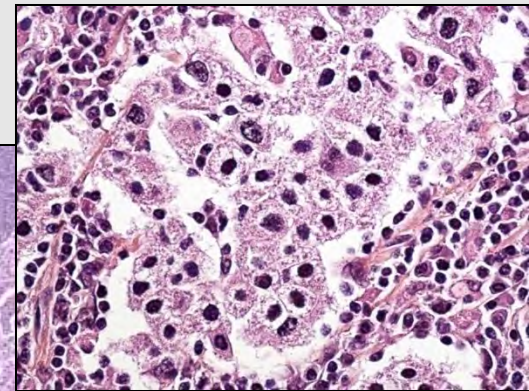
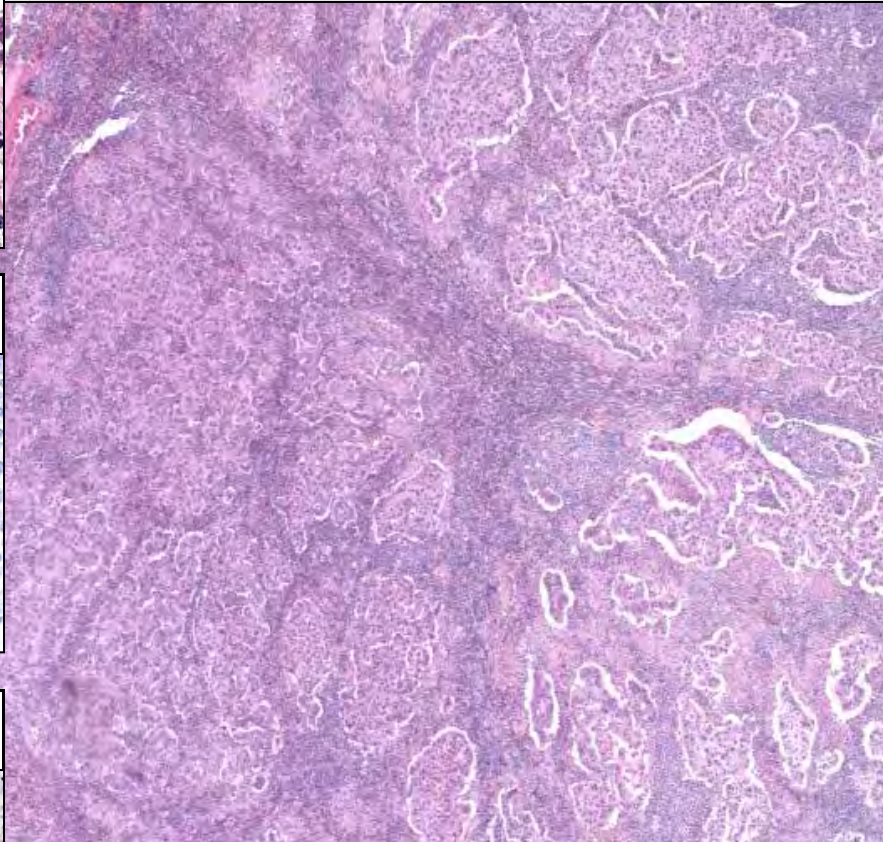
Adequate tissue block



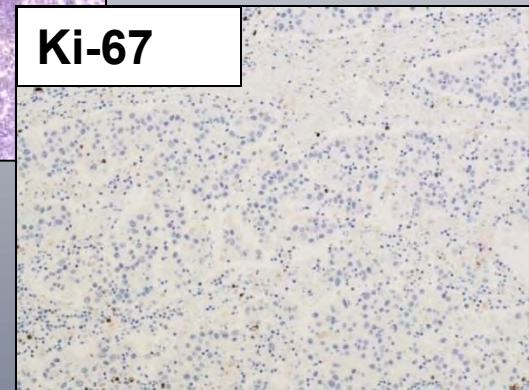
PanCK



Ki-67



PanCK



Ki-67

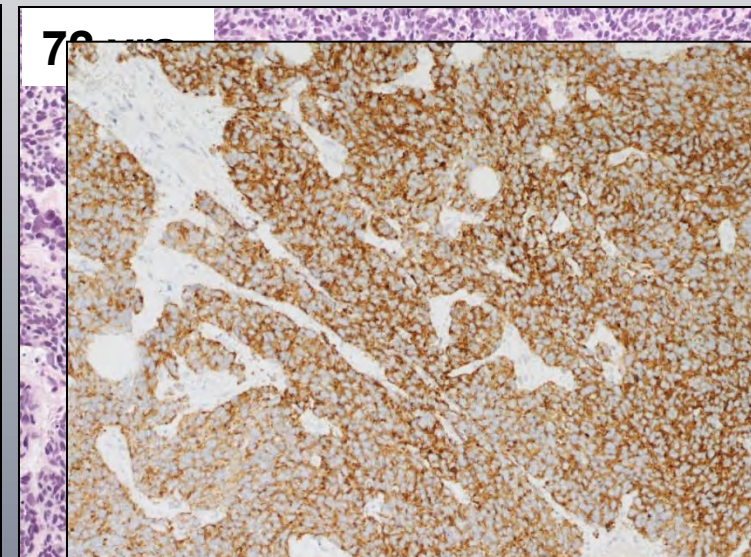
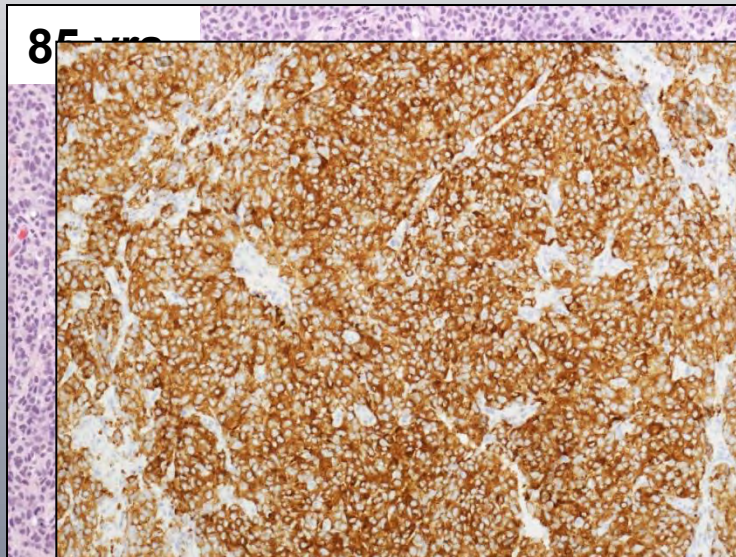
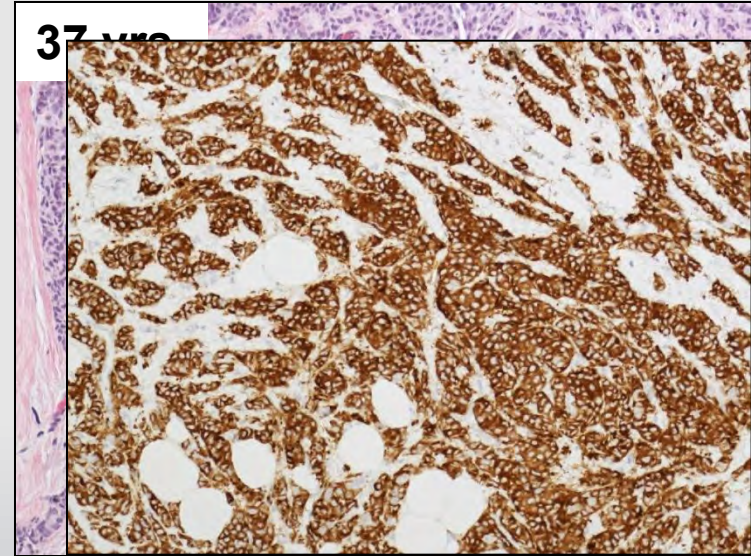
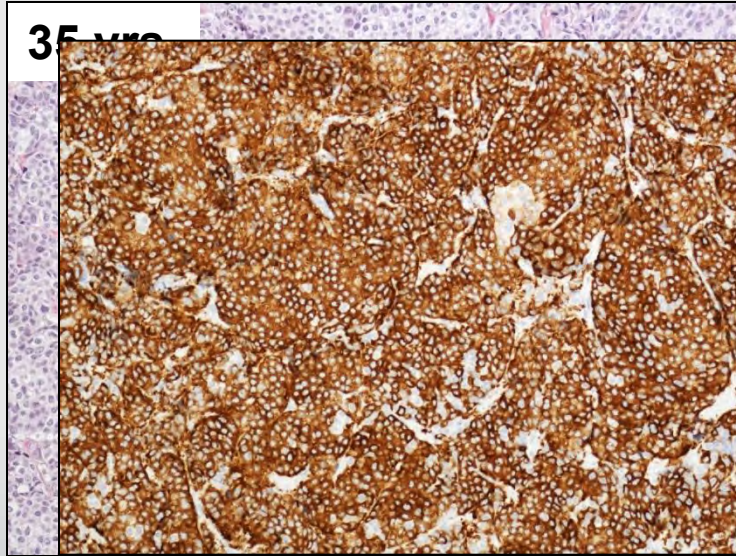
Adequate antibody panel

Constructing the adequate antibody panel requires proper interpretation of morphology in a context of clinical data and a knowledge of immunophenotypes of the tumors including their immunophenotypic variations.

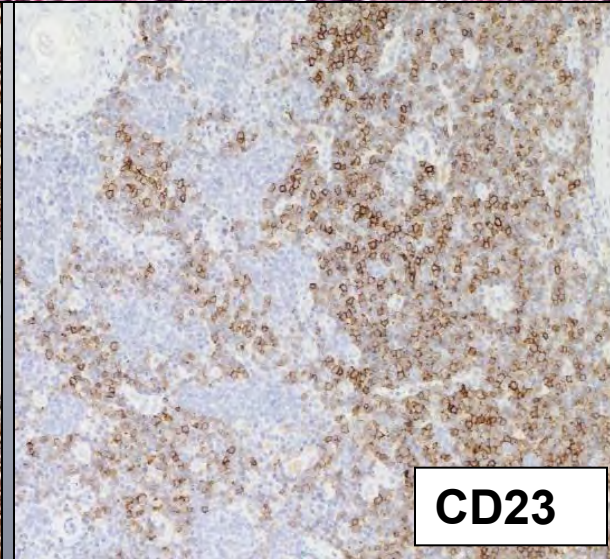
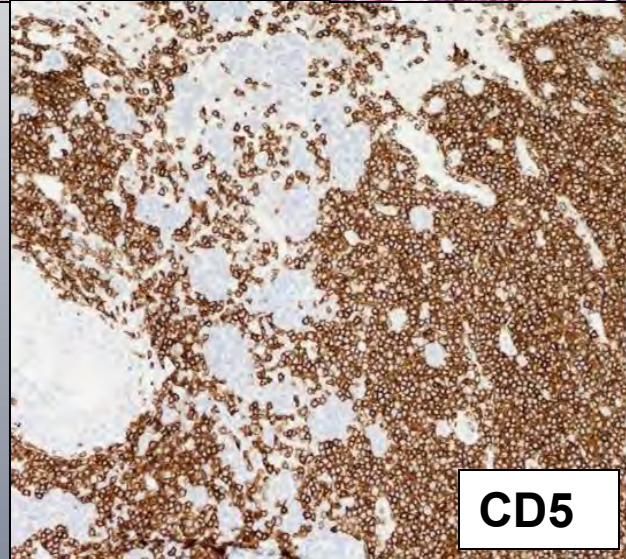
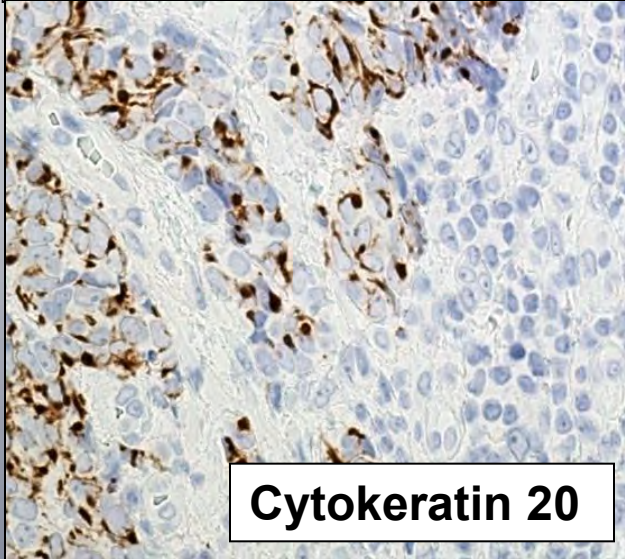
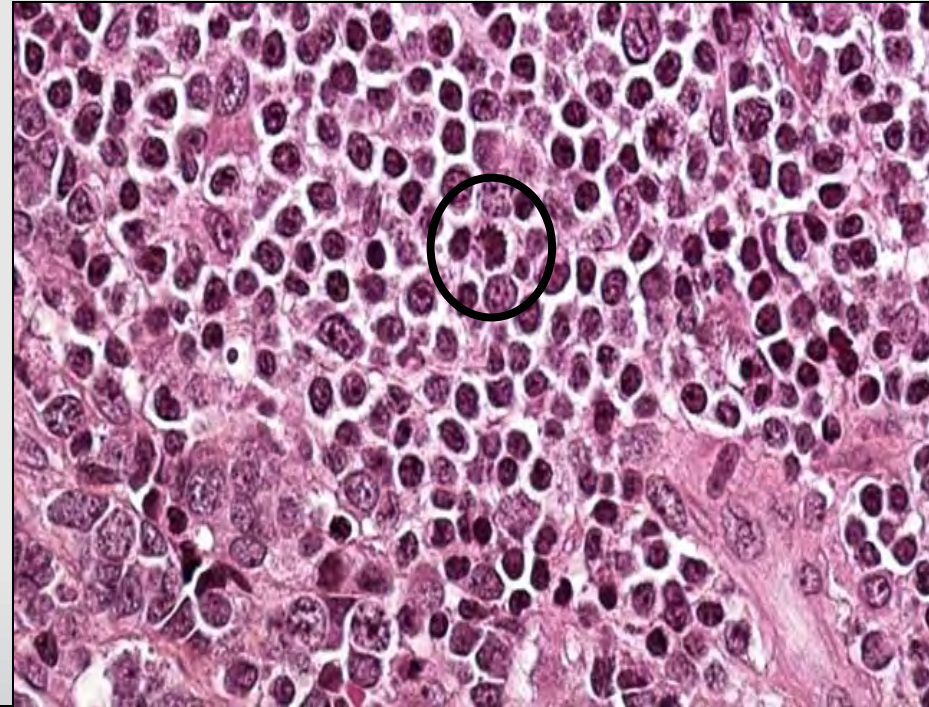
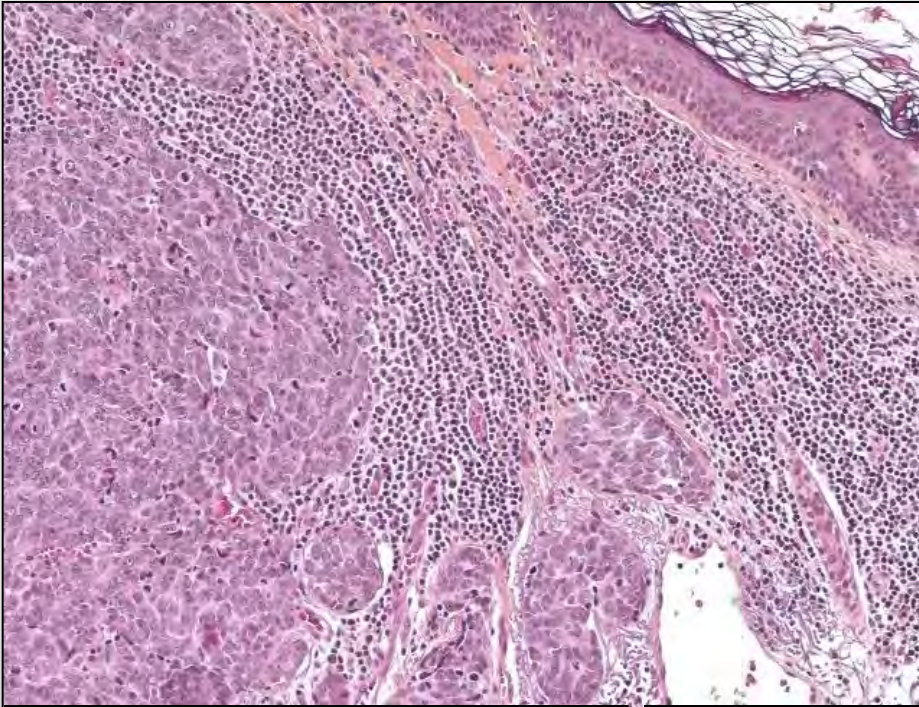
“Questions if not asked may never be answered”

4 different breast biopsies

Which cancer is of the neuroendocrine type?

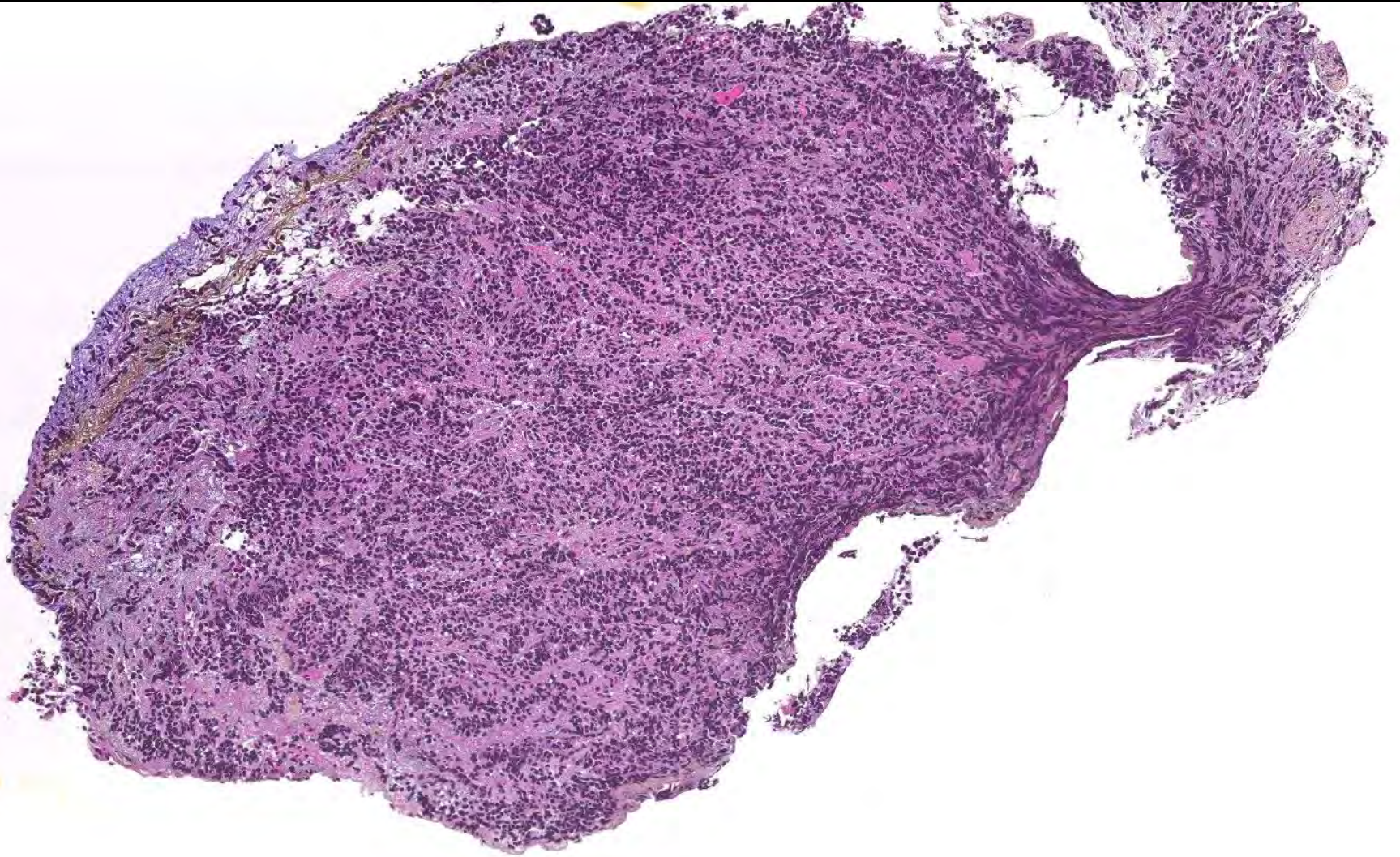


Merkel cell carcinoma and B-CLL

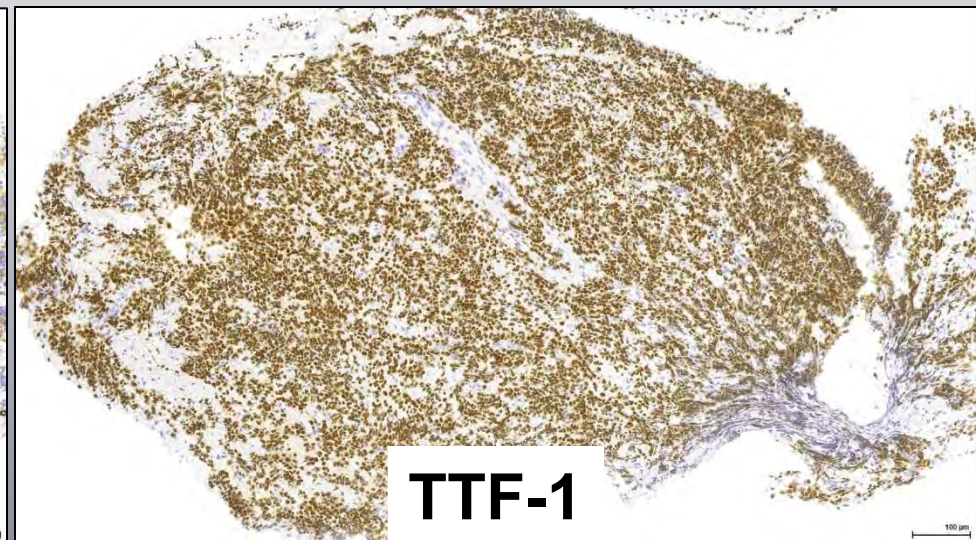
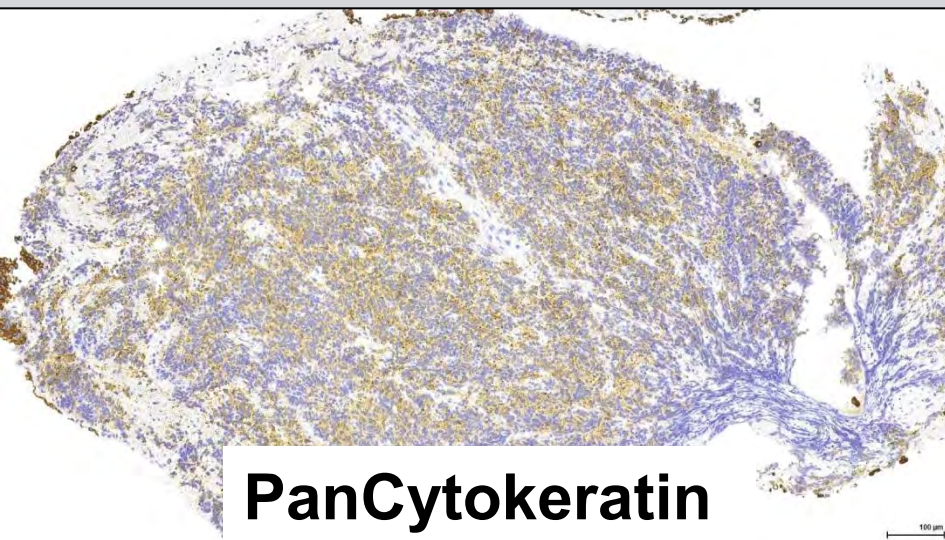
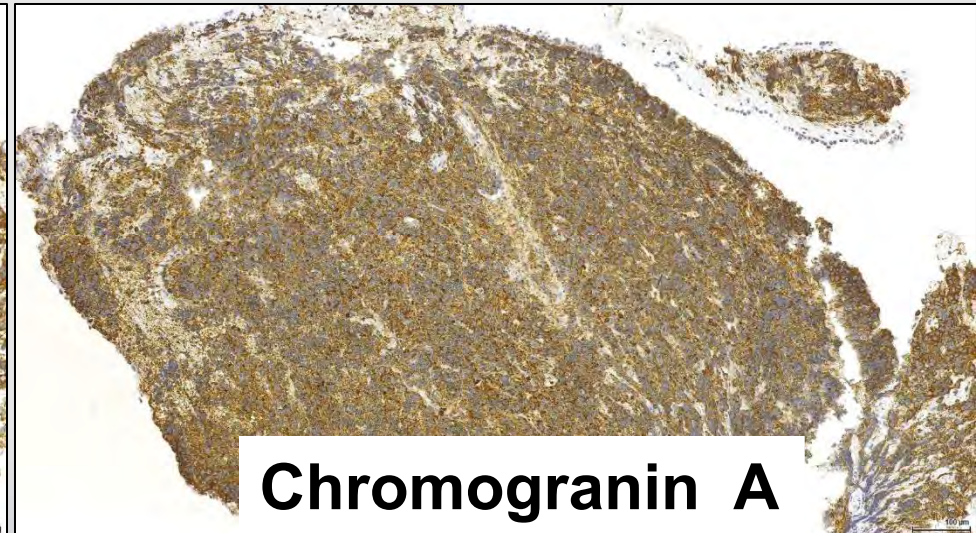
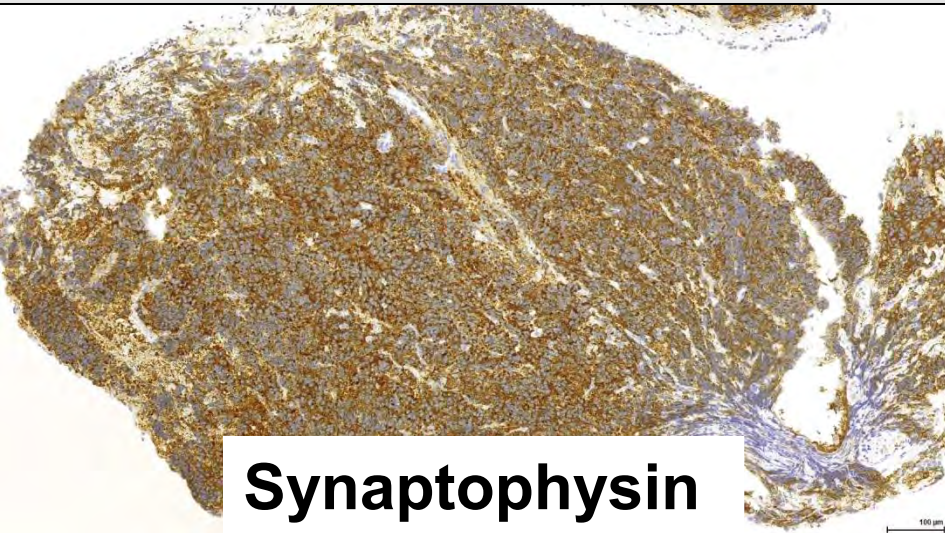

Biopsy of bronchial tumor

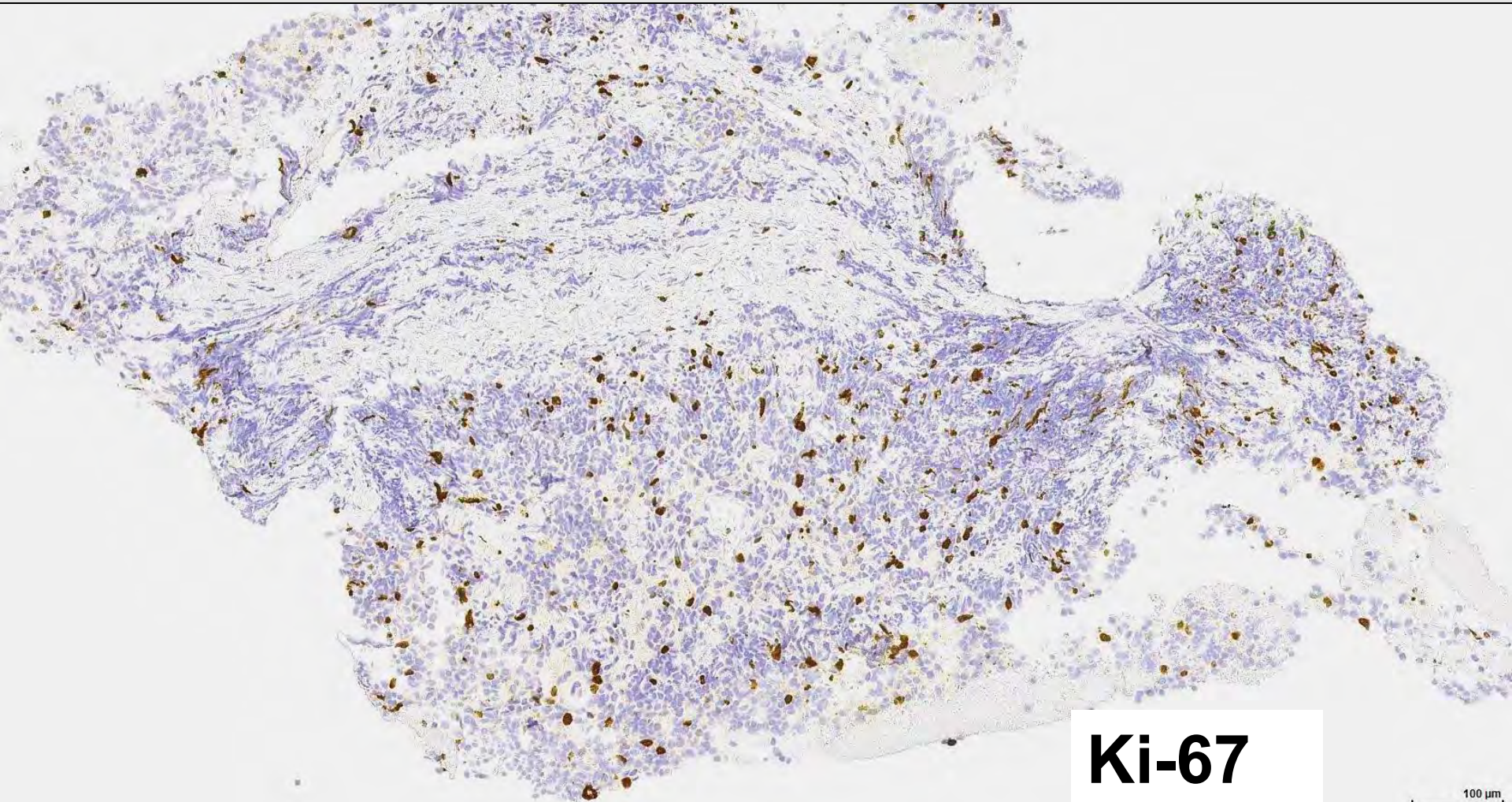
Man 68 yrs



Biopsy of bronchial tumor



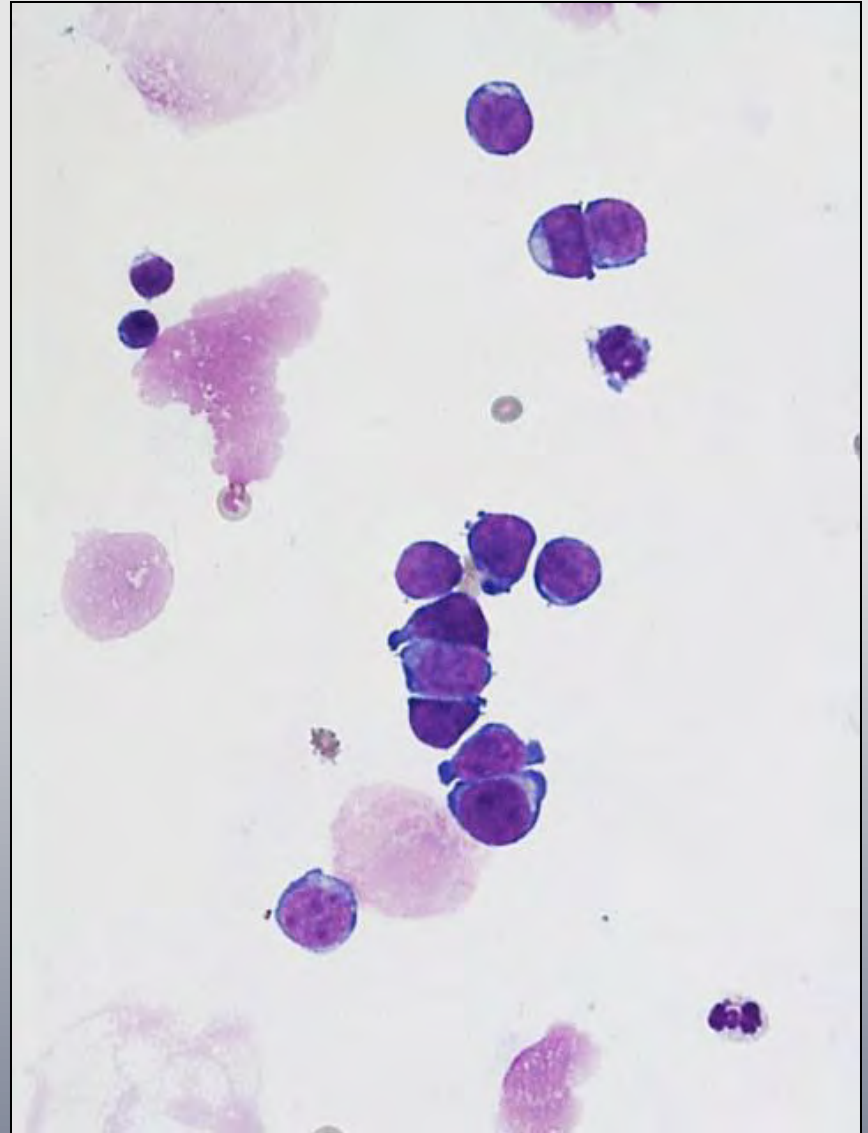
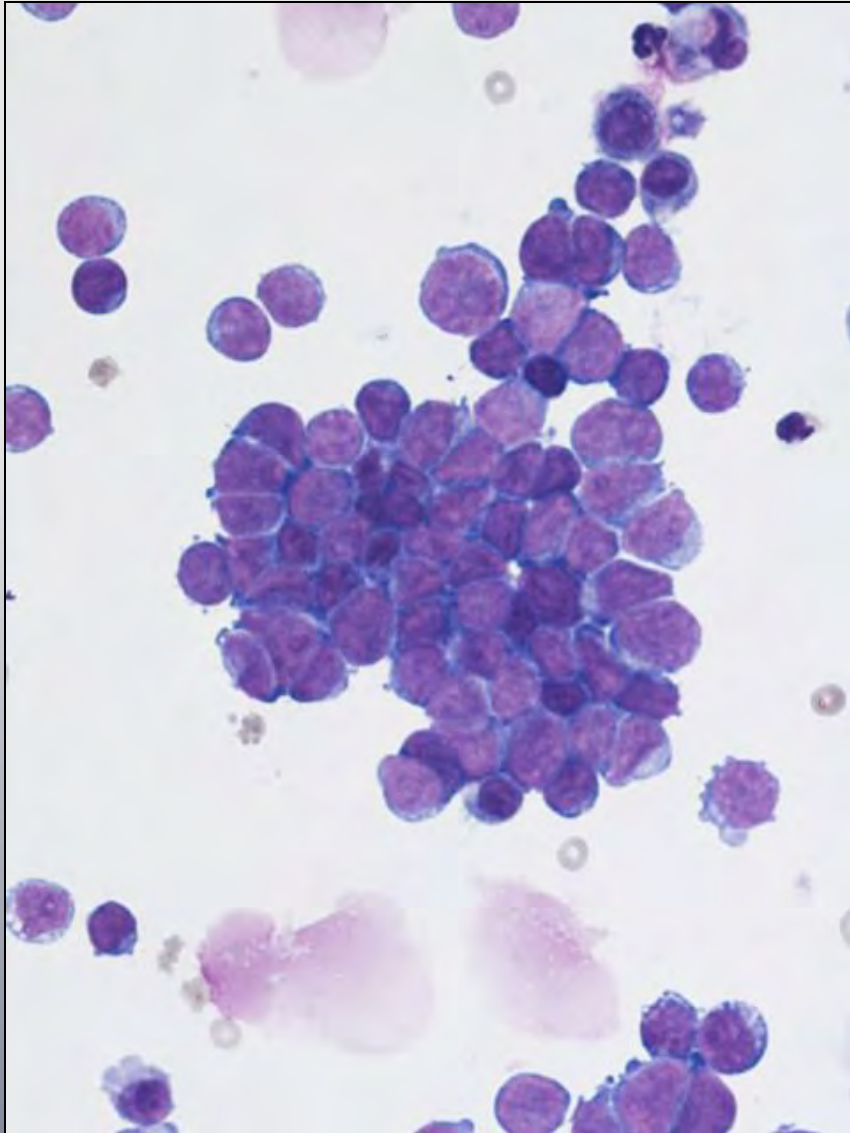
Biopsy of bronchial tumor



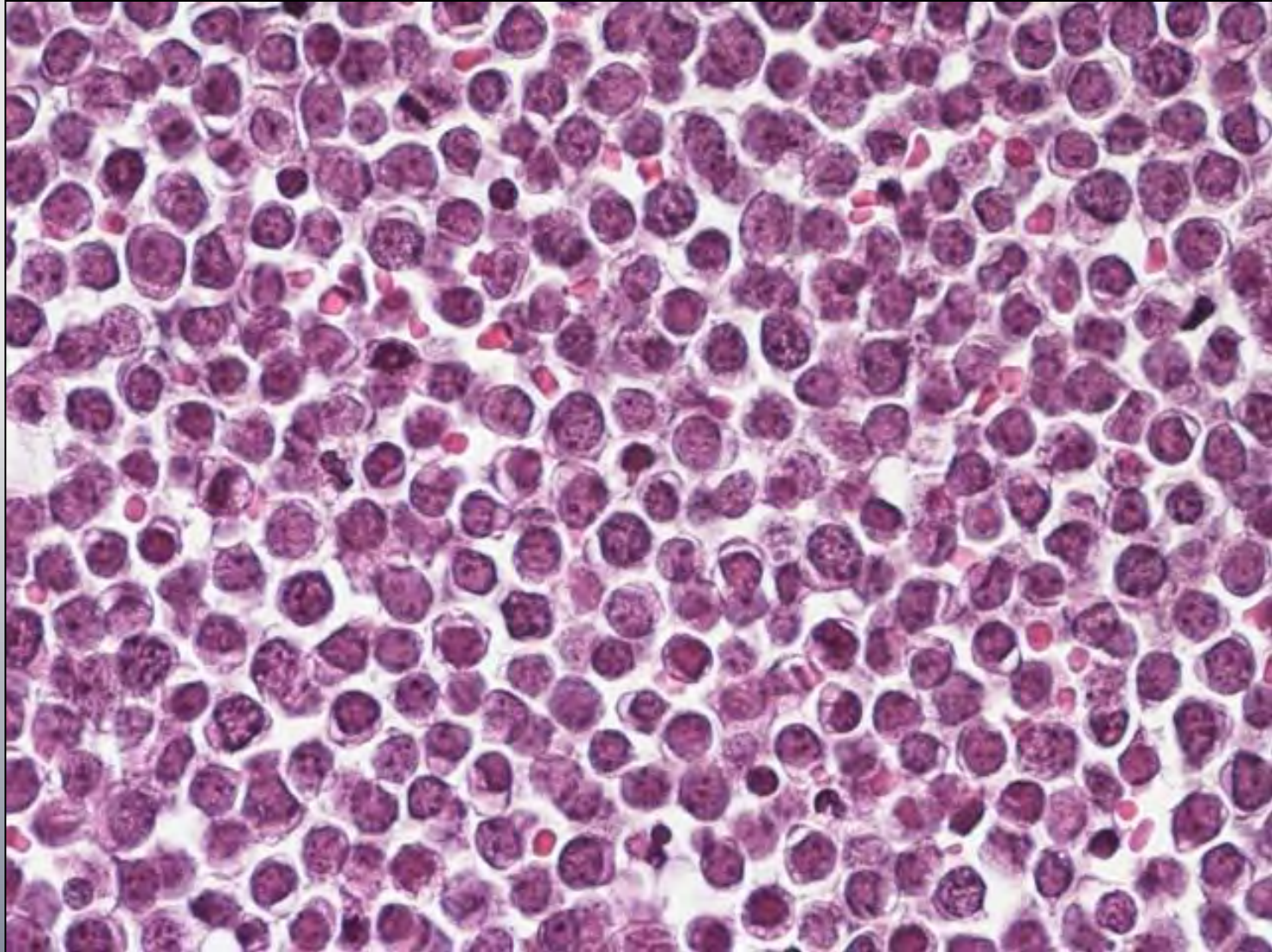
Ki-67

100 μm

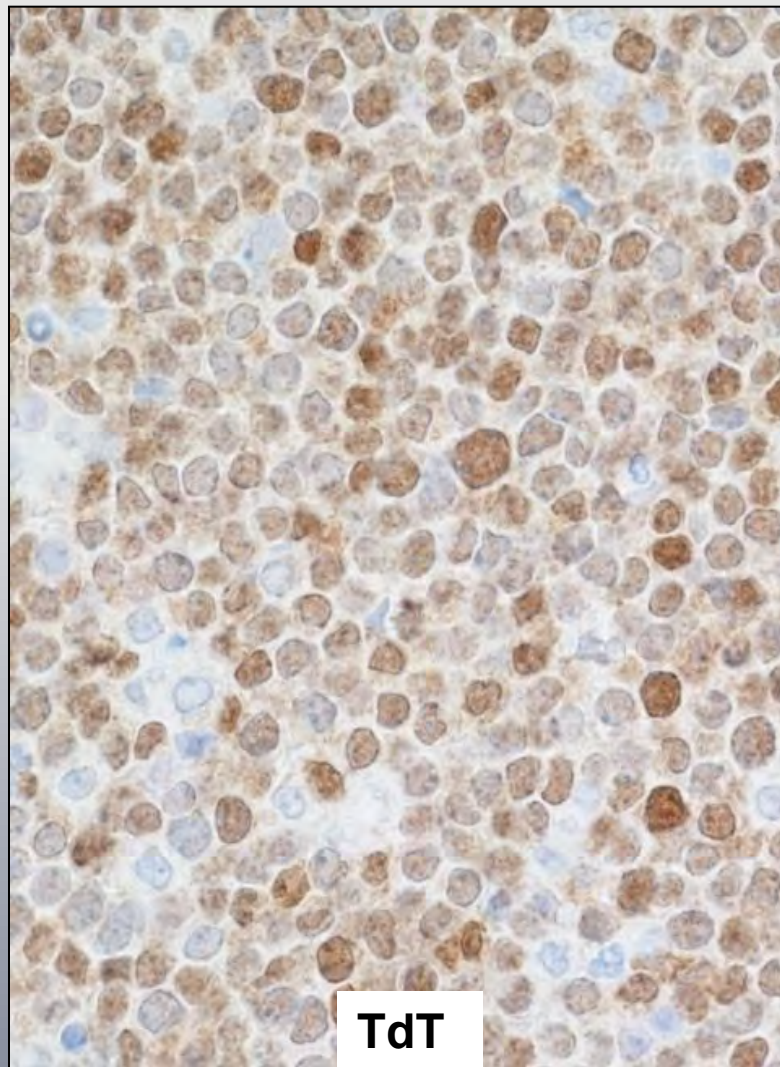
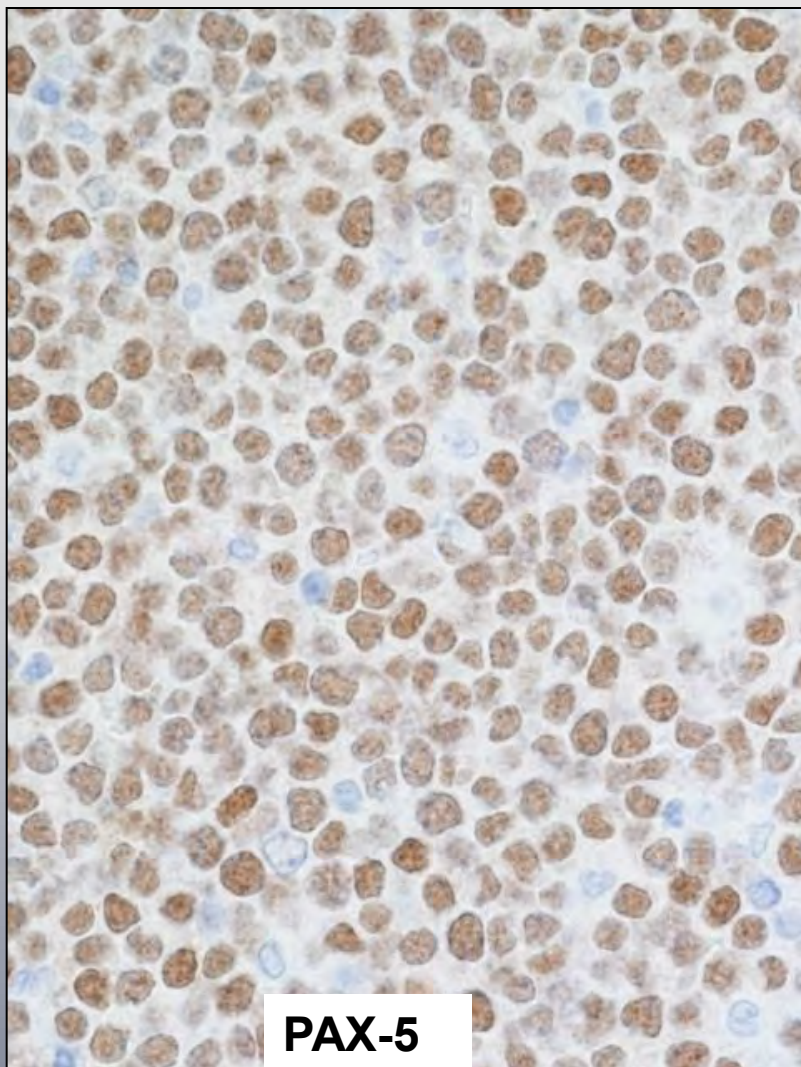
Pleural fluid – Man 84 yrs

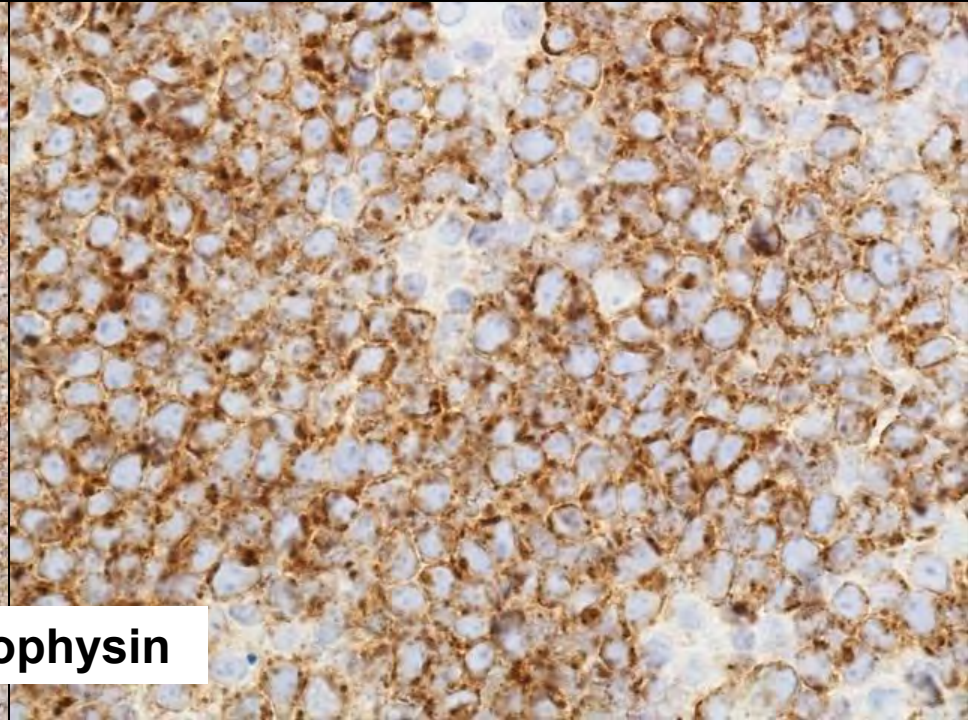
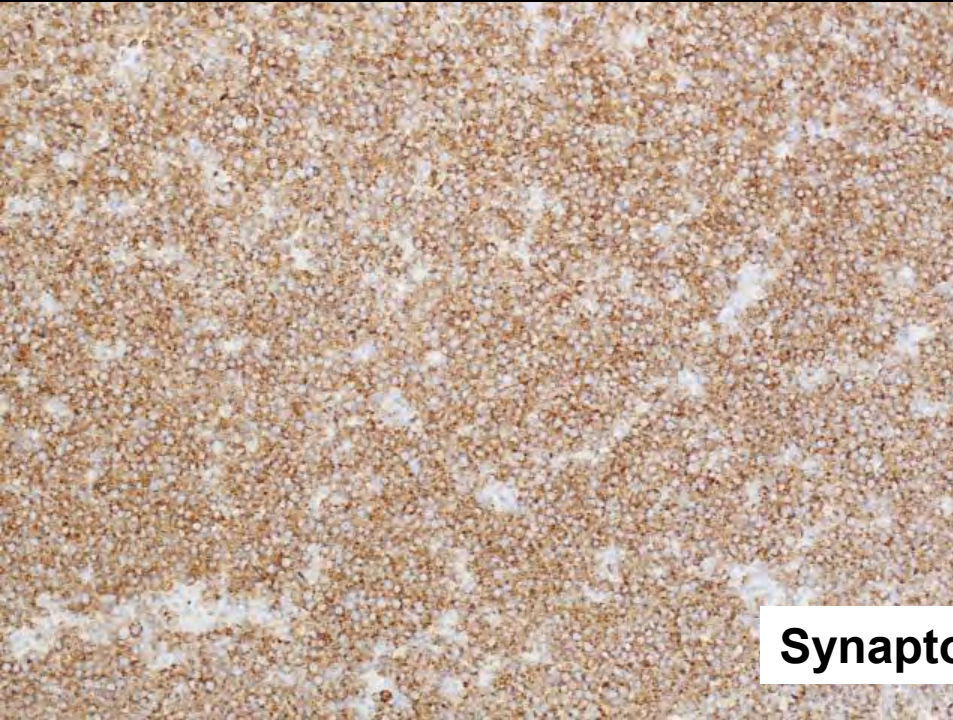
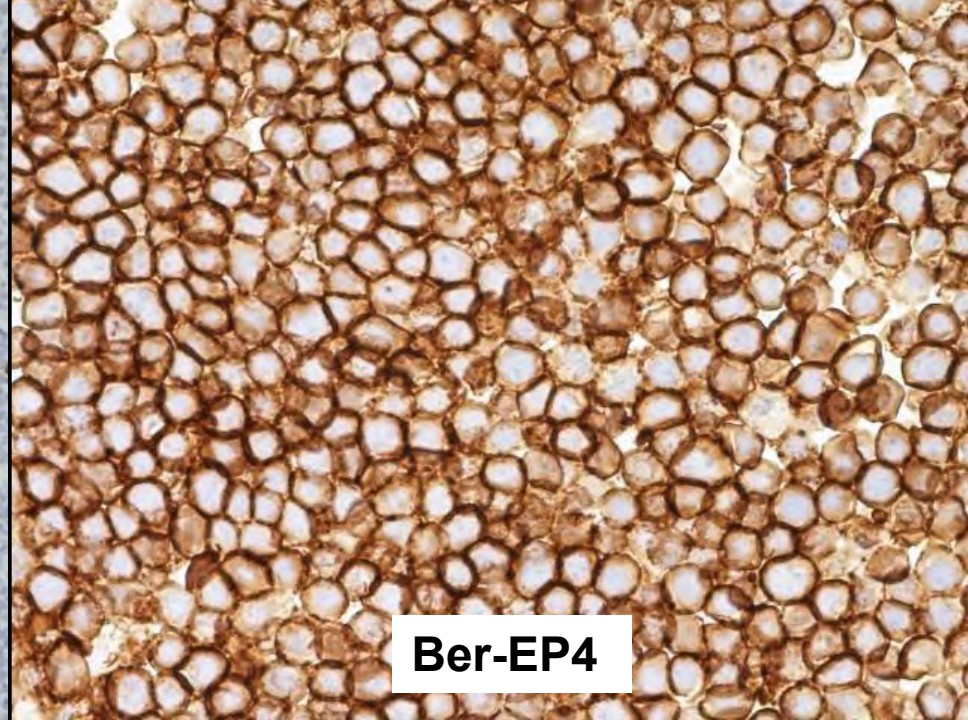
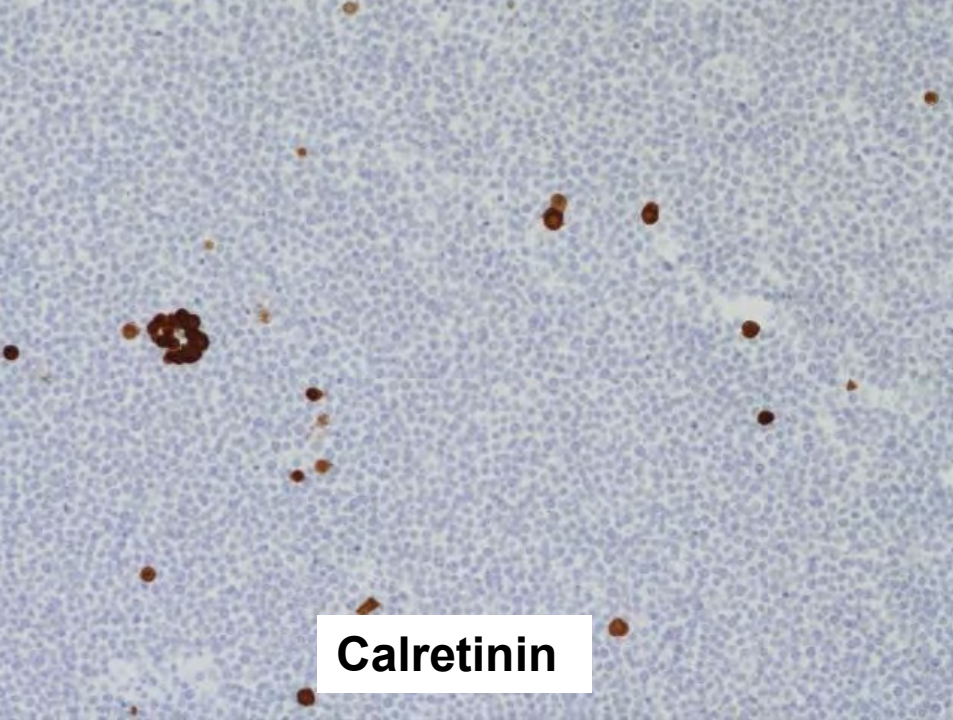


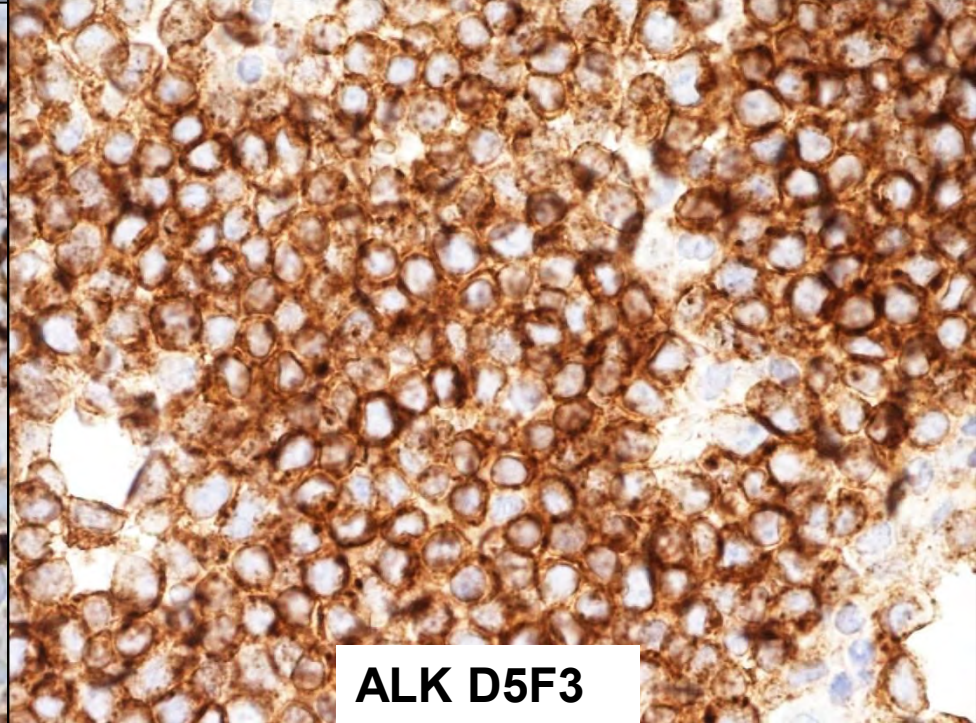
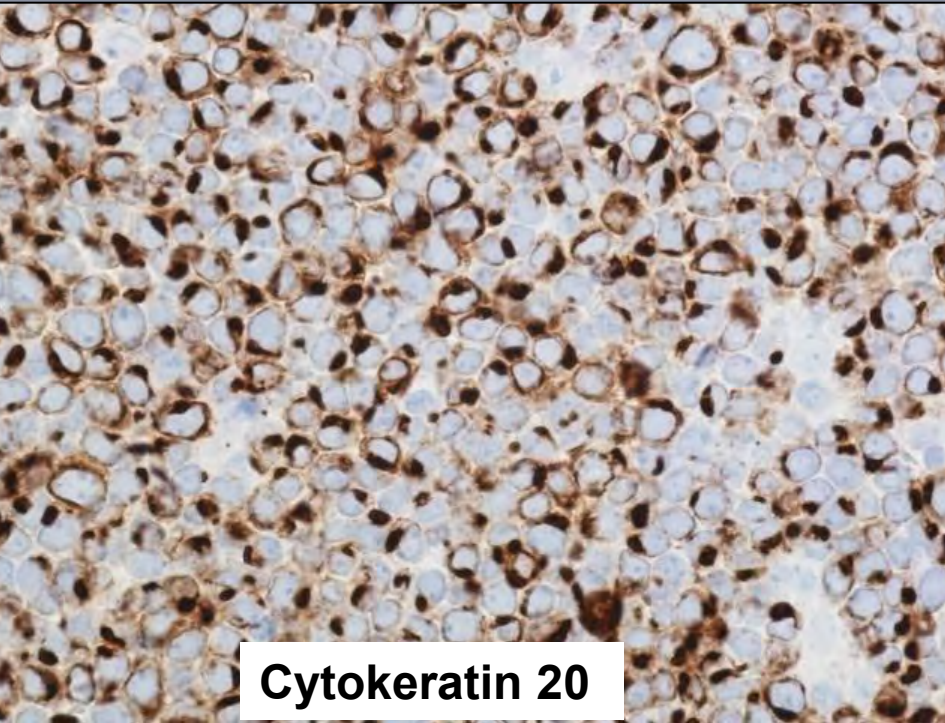
Pleural fluid - cell block



Pleural fluid IHC on the cell block







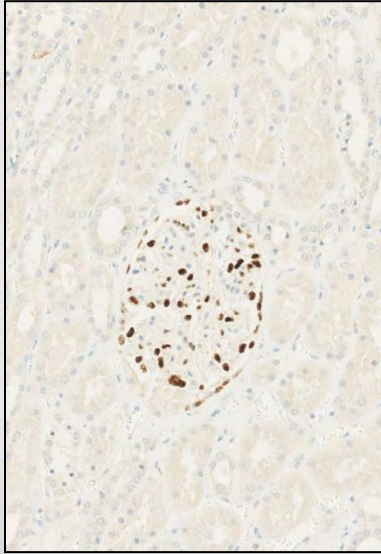
**Dg: Metastatic Merkel cell carcinoma
in pleura**

Adequate antibody clone

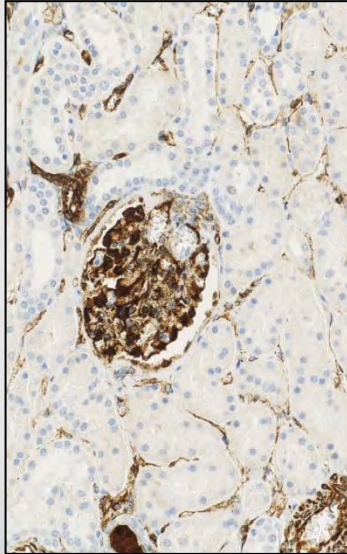
**Use antibody clone with known
spectrum of reactivity!**

Staining pattern of WT1 - different clones ... and protocols

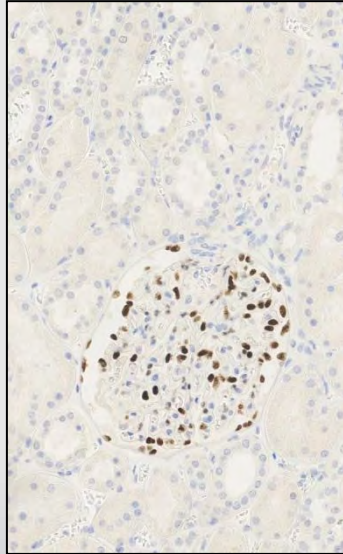
6F-H6 Opt



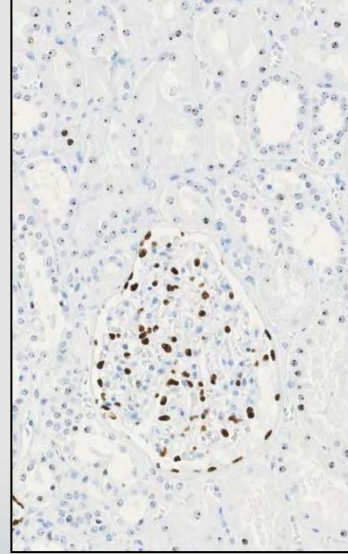
6F-H6 Opt



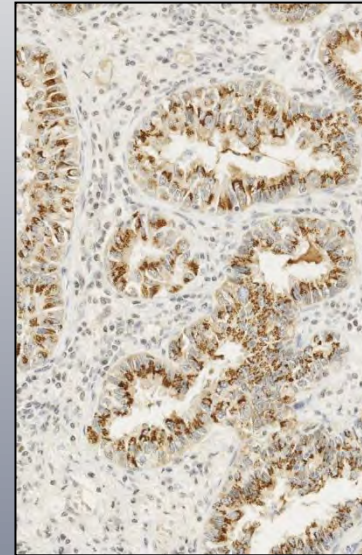
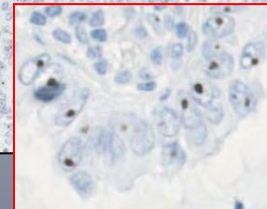
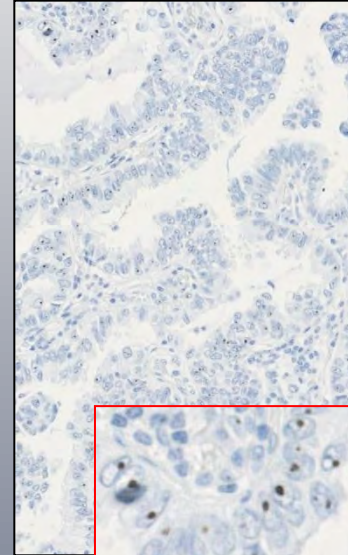
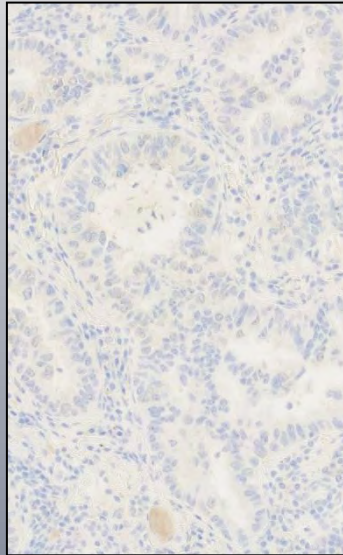
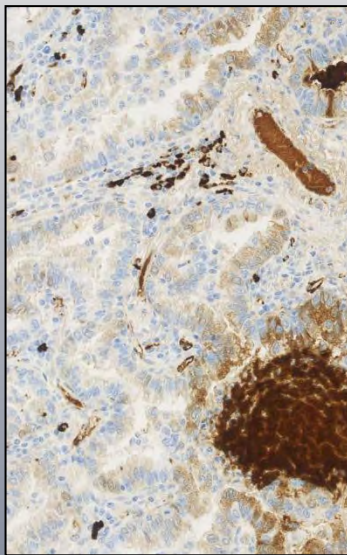
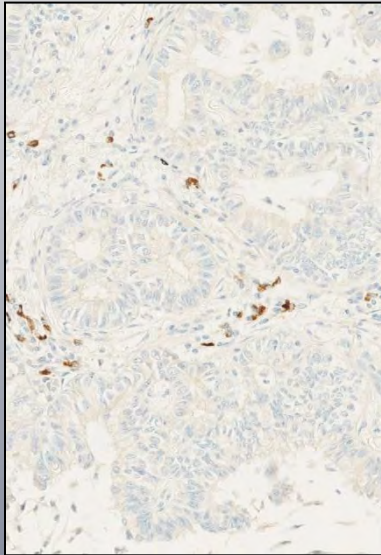
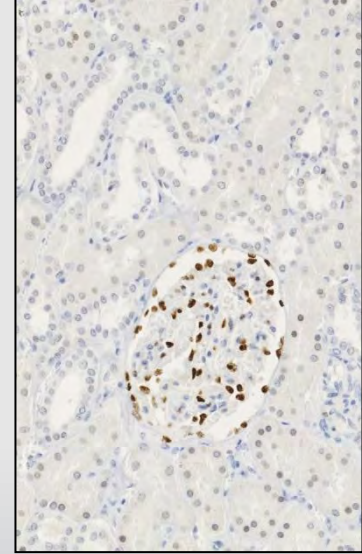
WT49 Opt



EP122 Opt

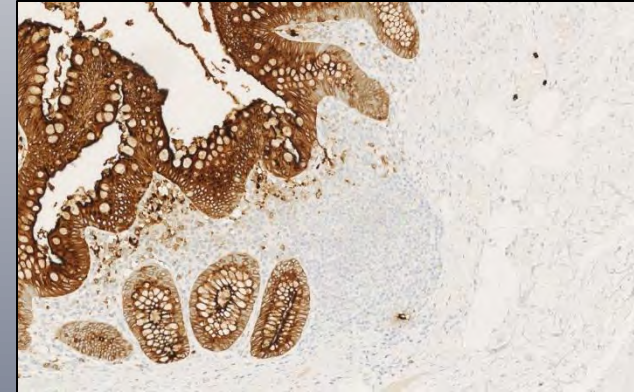
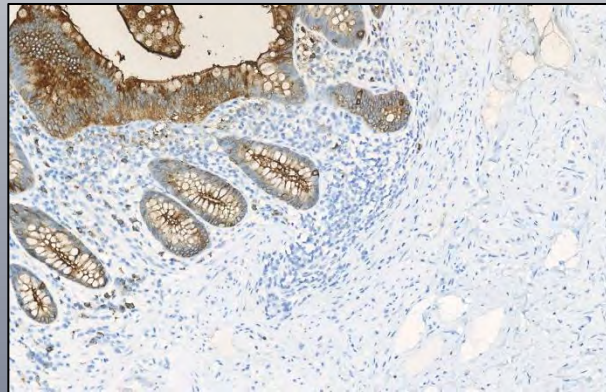
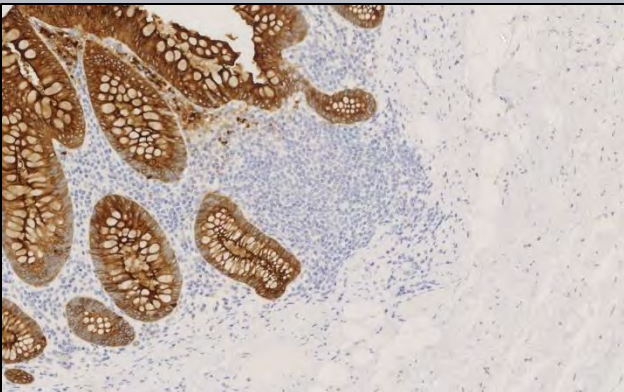
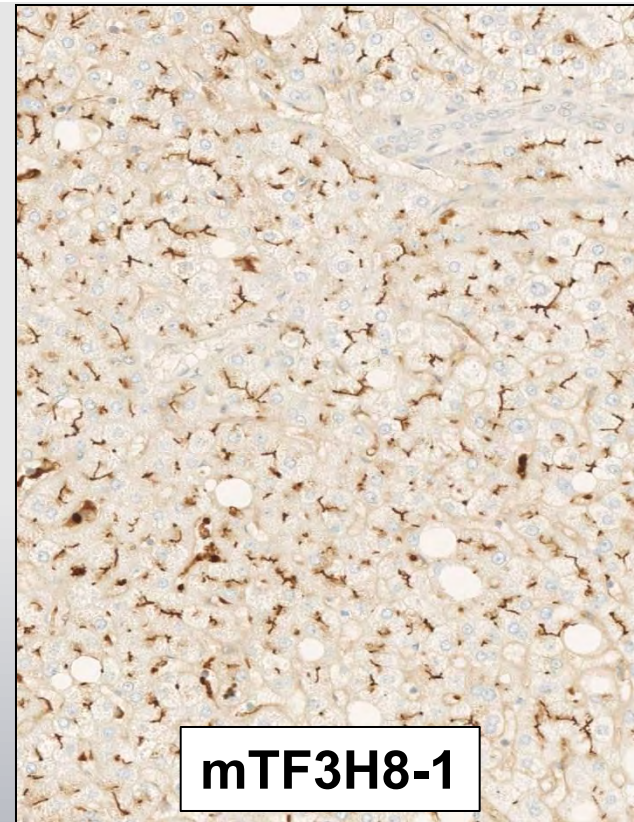
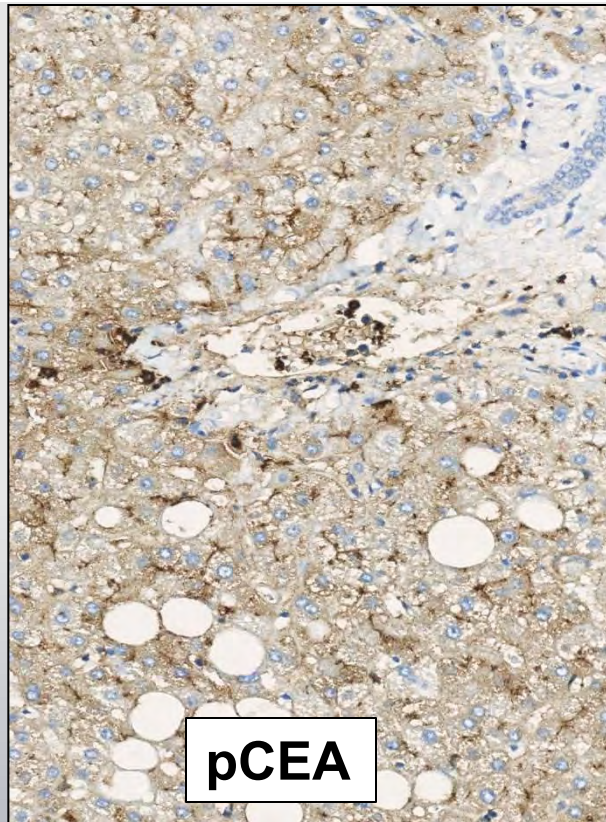
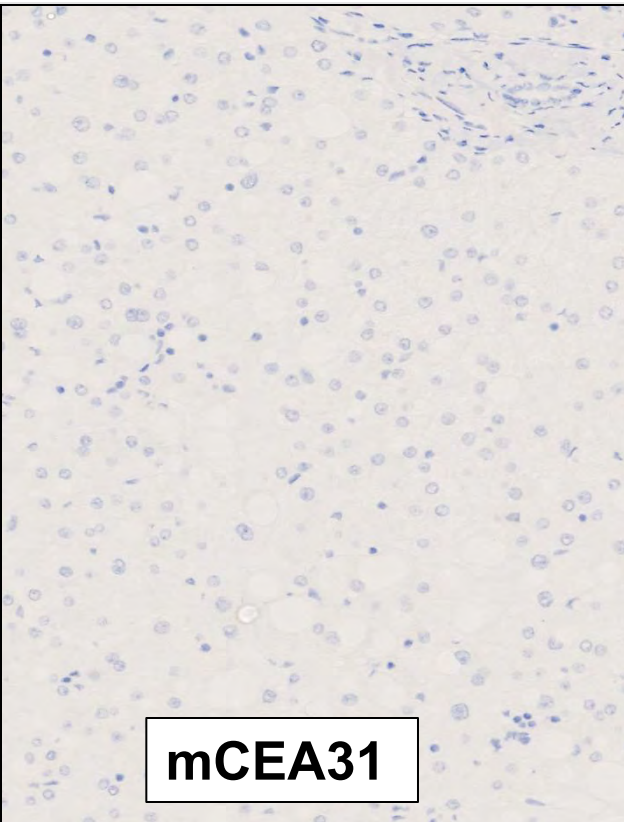


MX012 Good

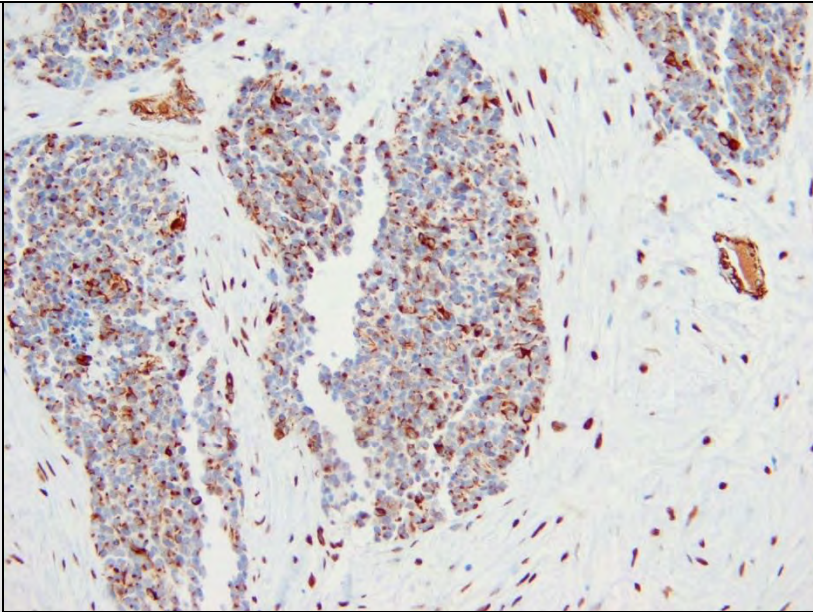


Run 47 NordiQC:

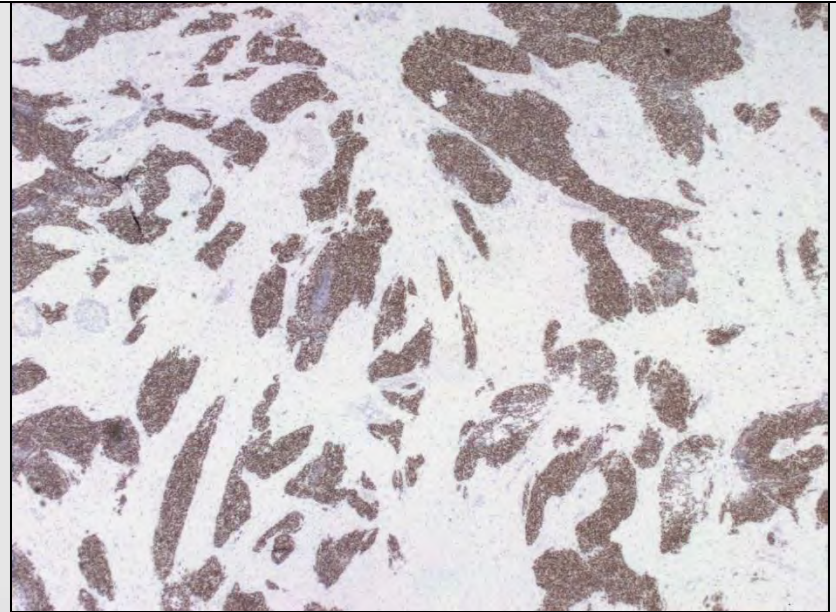
CEA antibodies = 8 different mCEA clones = 15 products; pCEA excluded.



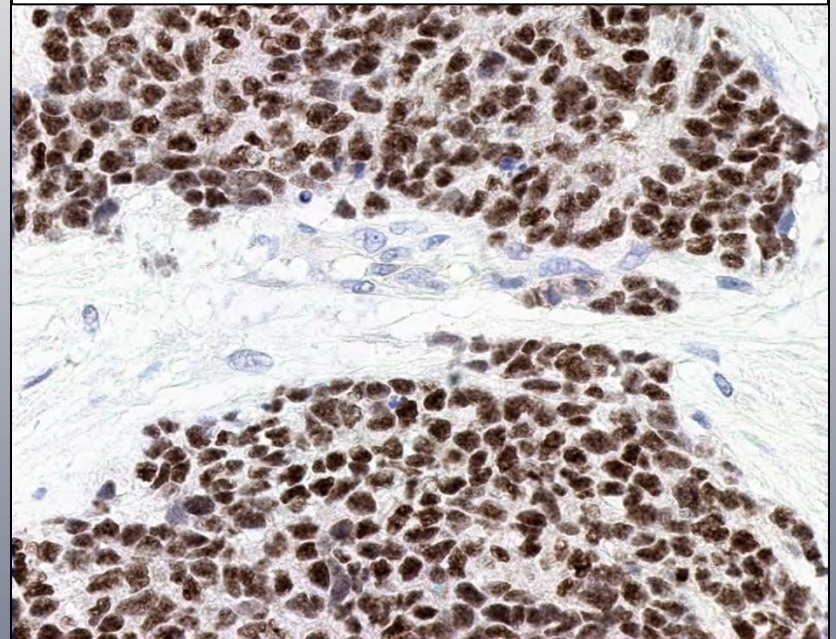
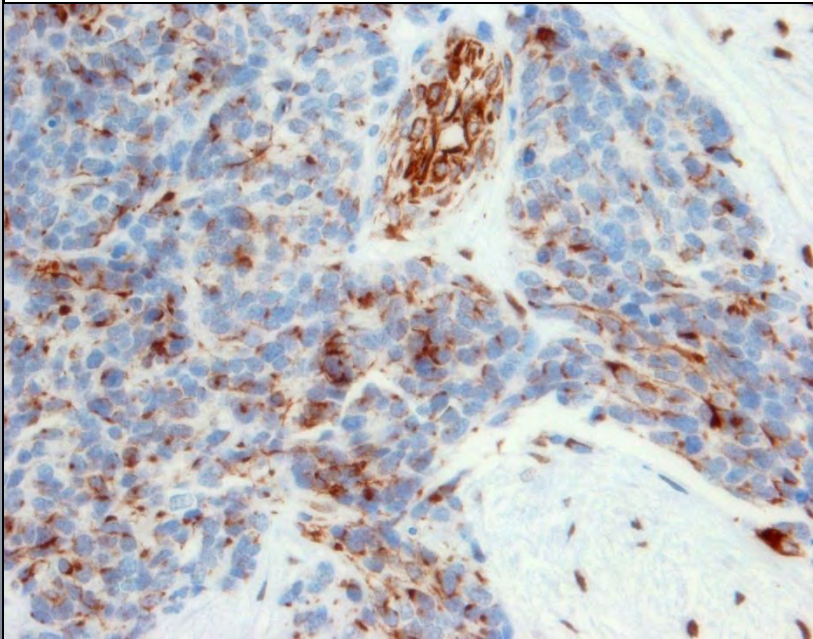
Desmoplastic small round cell tumor



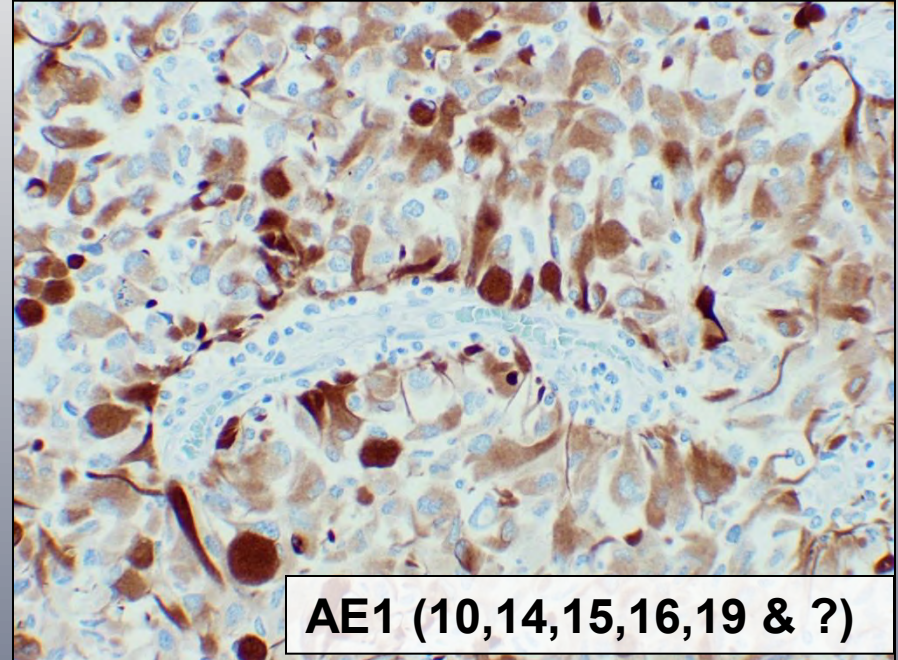
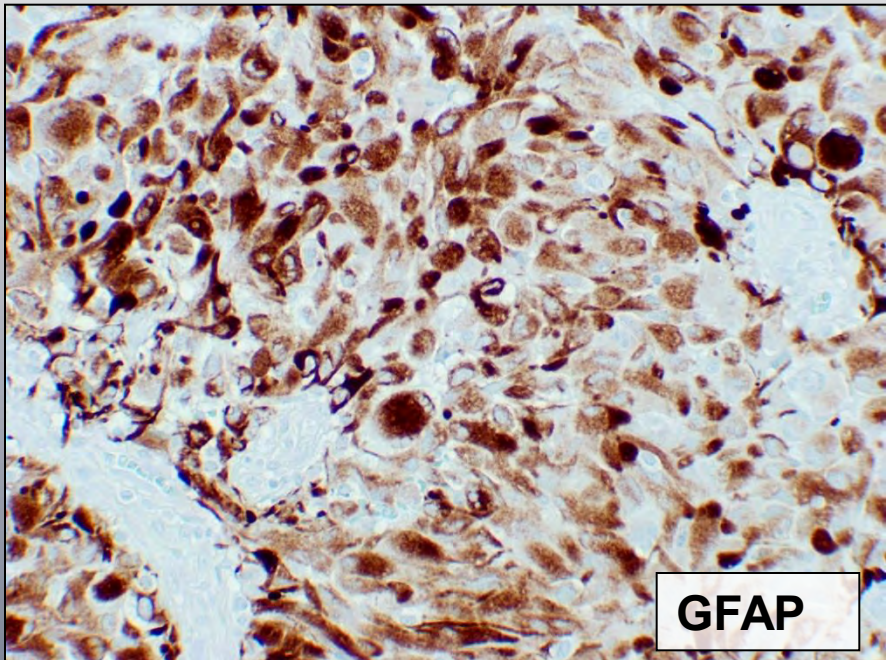
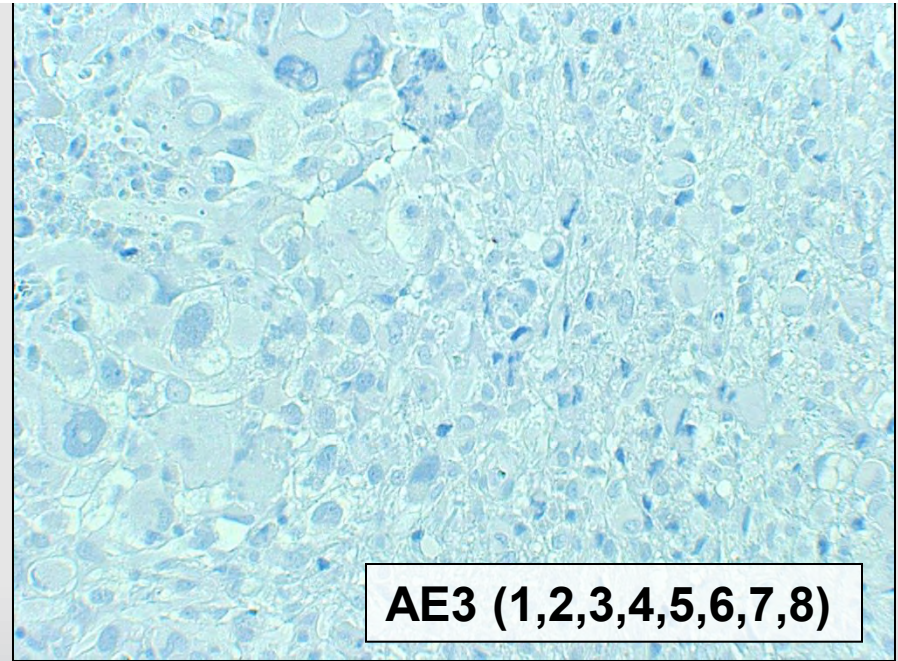
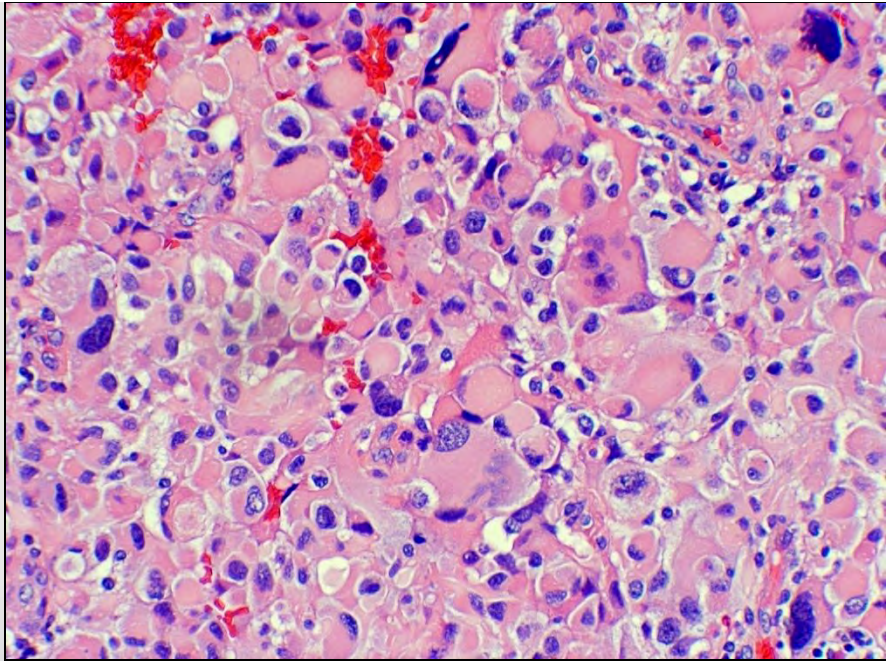
WT-1 clone 6F-H2 (N-terminal)



WT-1 clone C-19 (C-terminal)

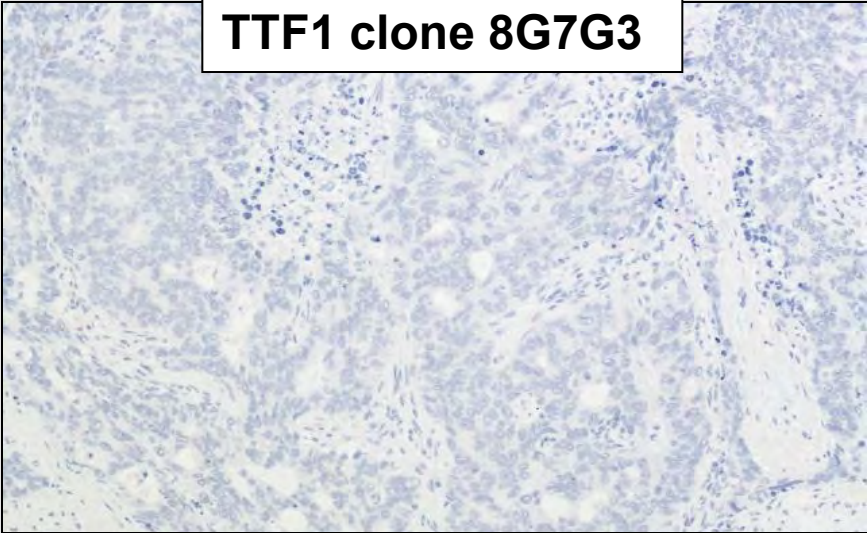


Keratin staining with AE1/AE3 clones in glioblastoma

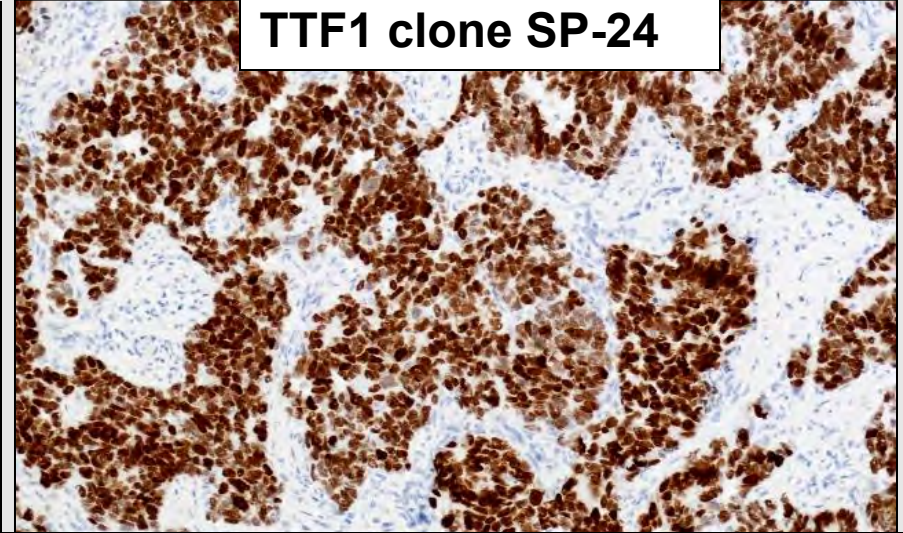


Thyroid Transcription Factor-1

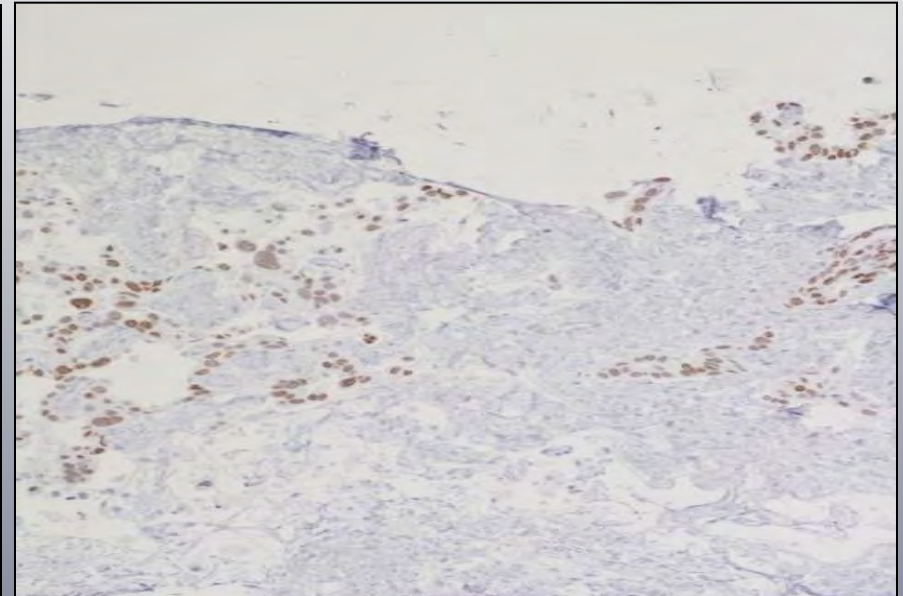
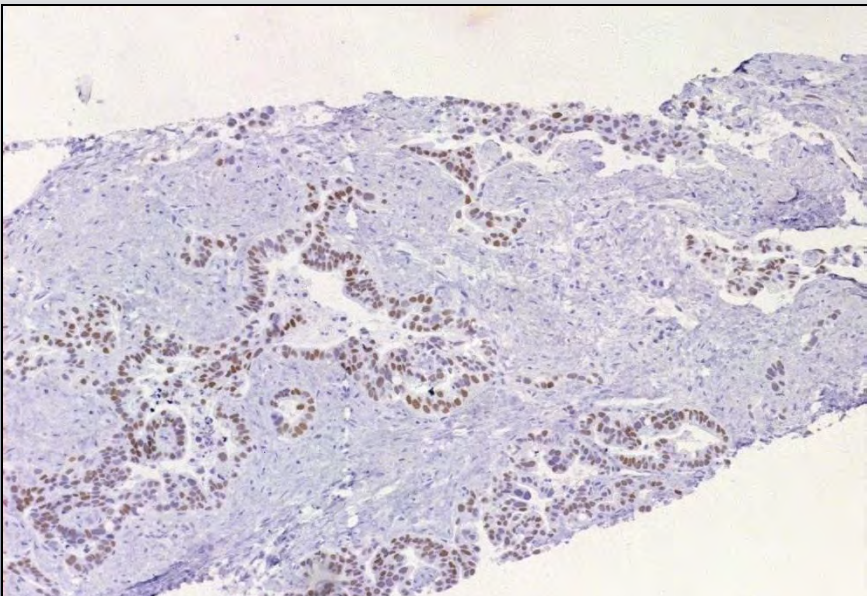
TTF1 clone 8G7G3



TTF1 clone SP-24



TTF1 positive primary colon adenocarcinoma



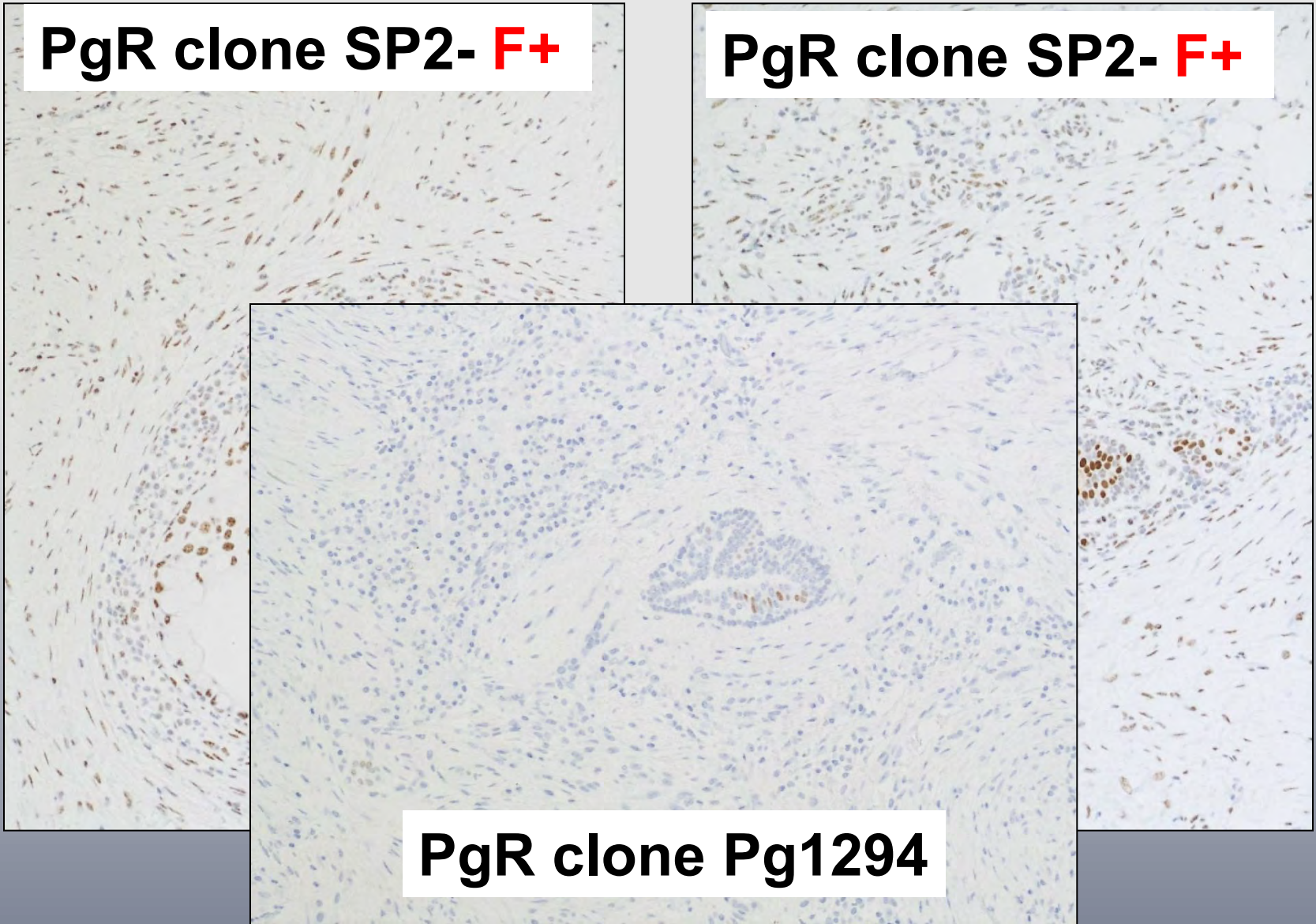
TTF-1 positive metastatic gallbladder carcinoma

Progesterone staining in mucoepidermoid carcinoma - breast

PgR clone SP2- F+

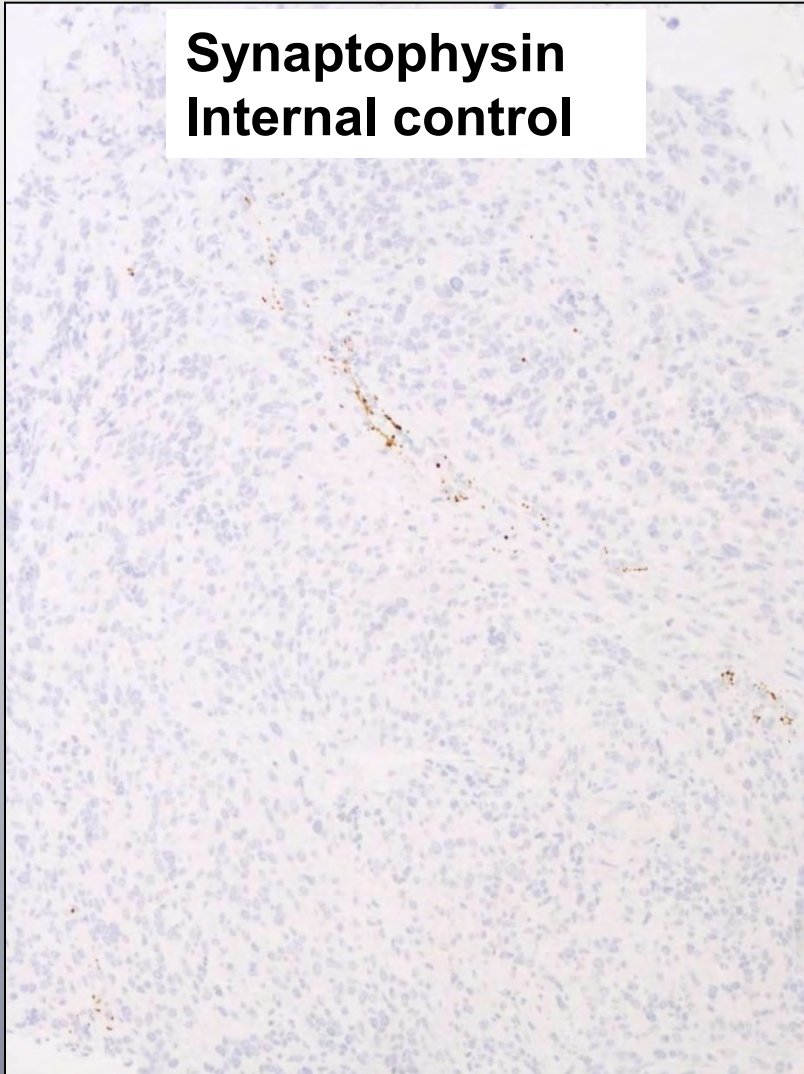
PgR clone SP2- F+

PgR clone Pg1294

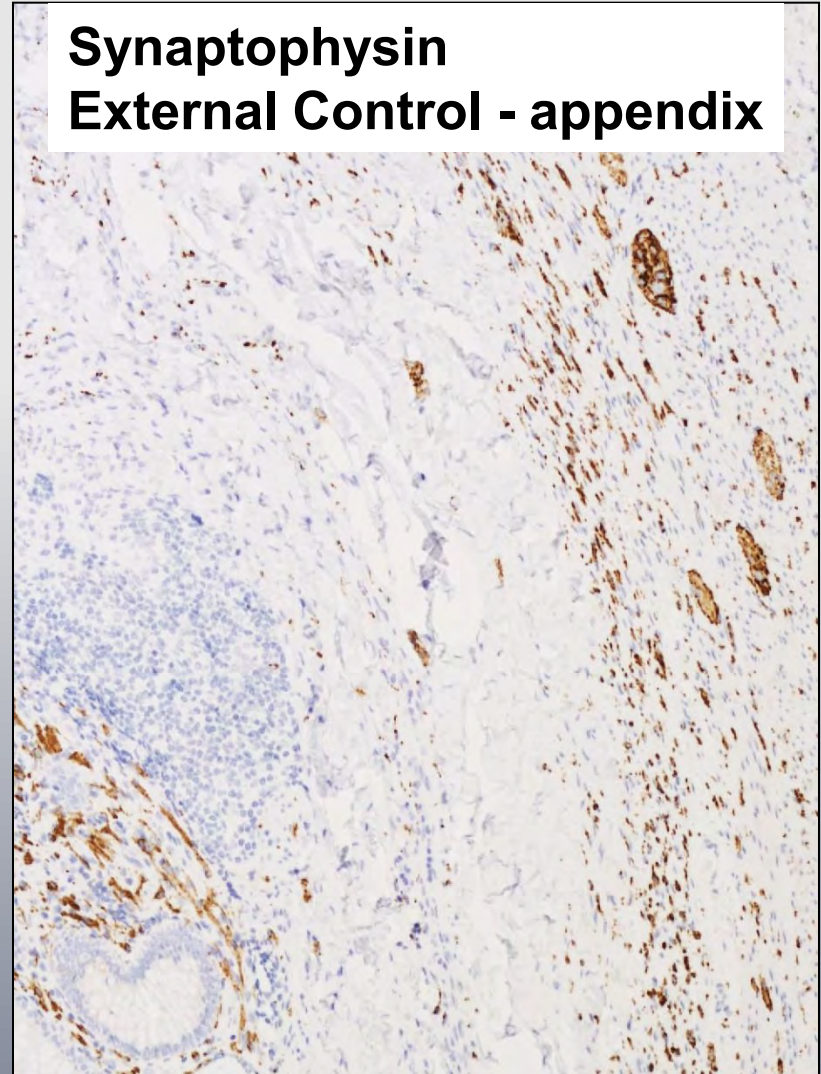


Adequate staining of internal and external controls

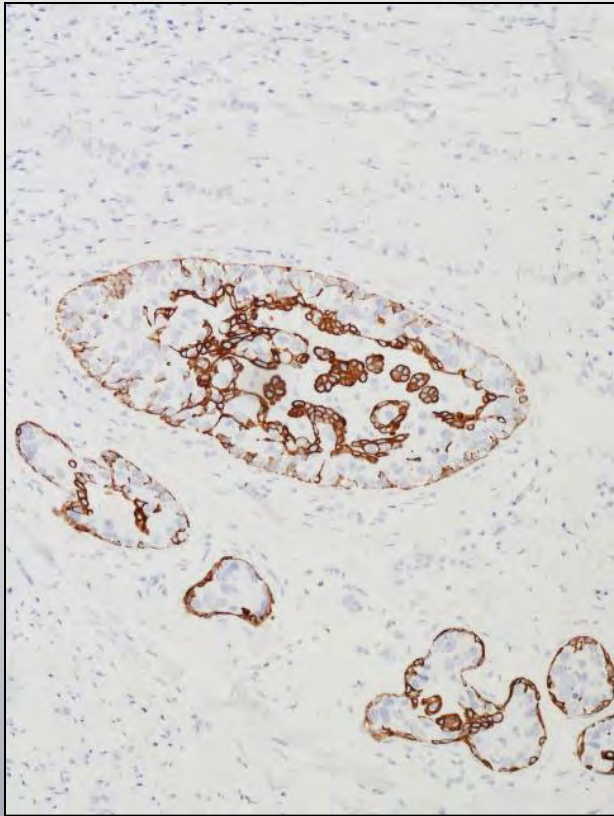
**Synaptophysin
Internal control**



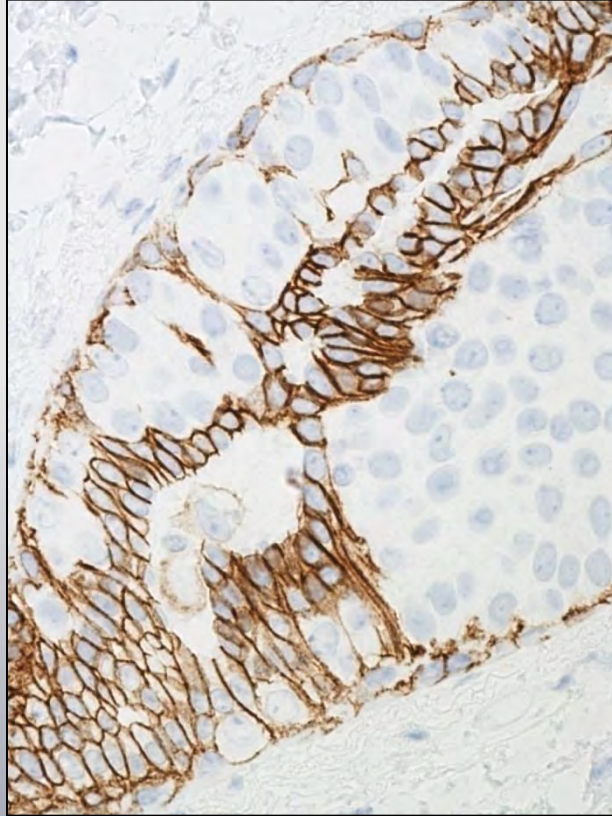
**Synaptophysin
External Control - appendix**



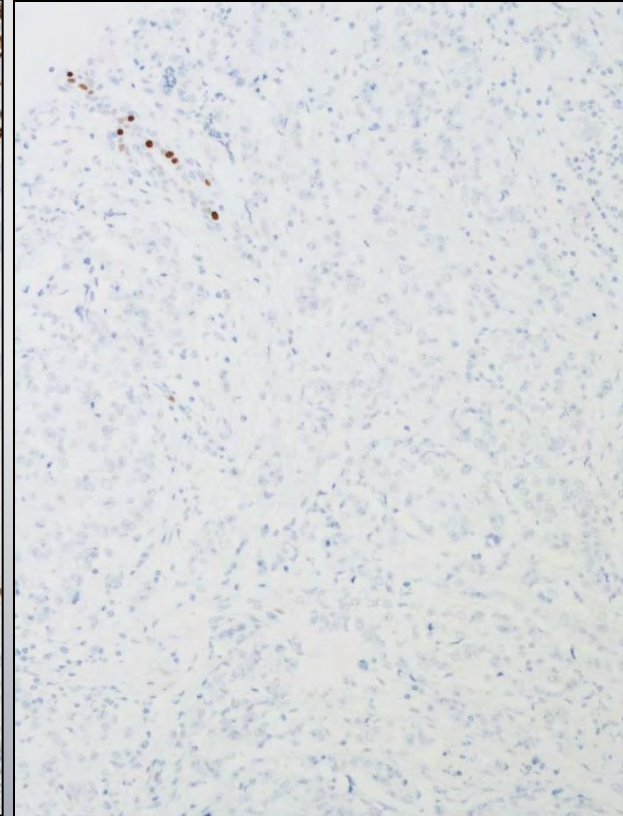
Breast carcinoma internal controls



Cytokeratin 5/6

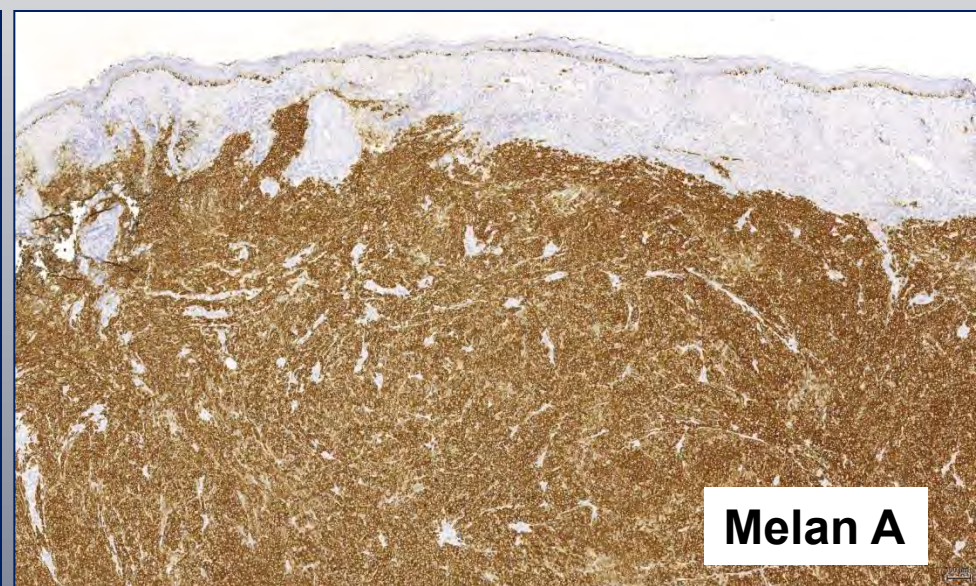
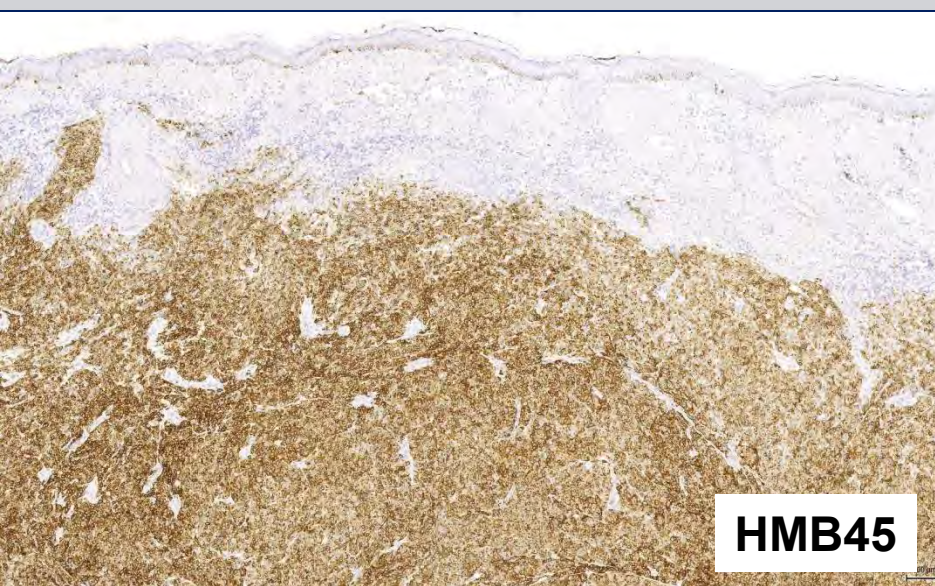
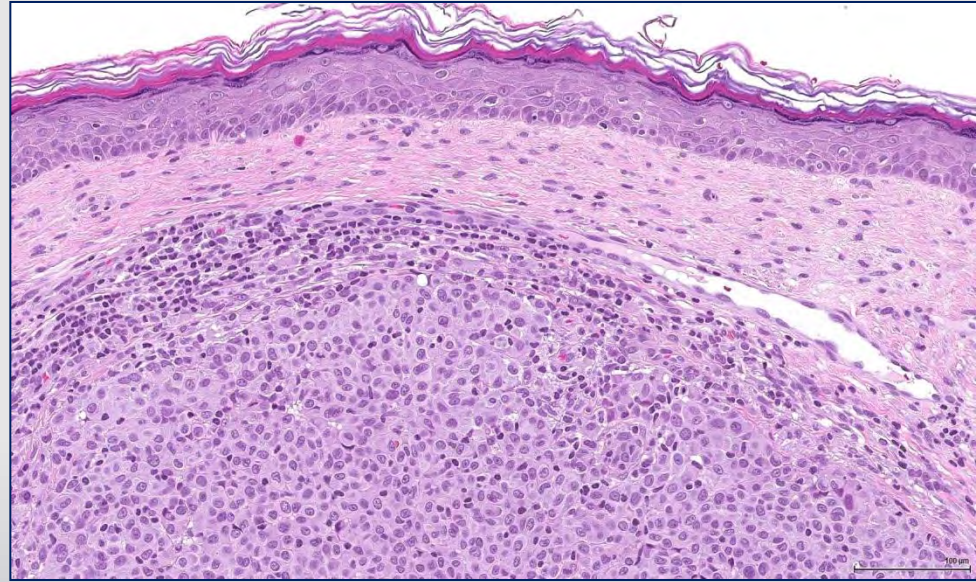
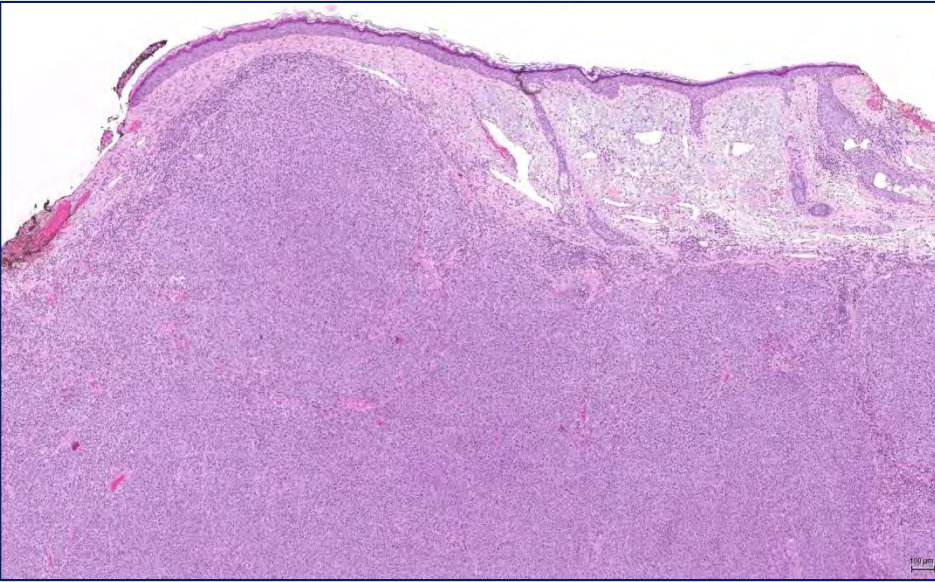


E-Cadherin



Estrogen Receptor

Metastatic malignant melanoma



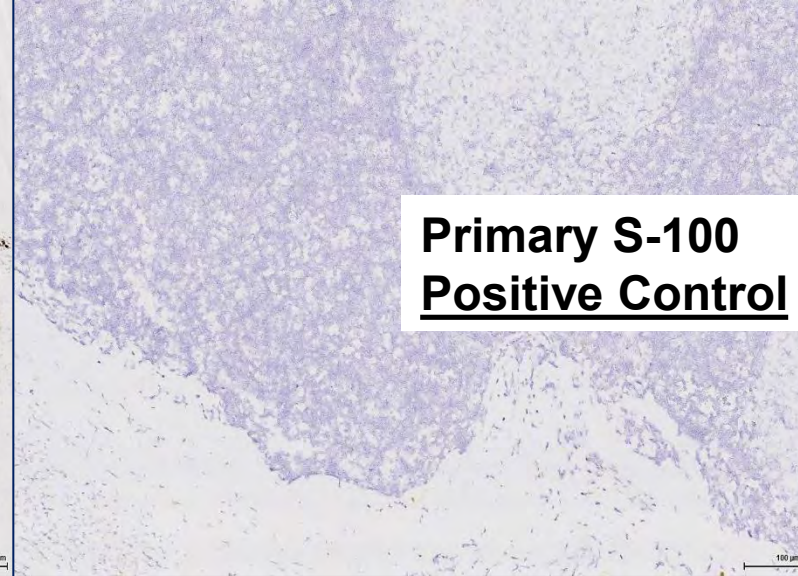
Metastatic malignant melanoma

S-100- ?

Primary S-100



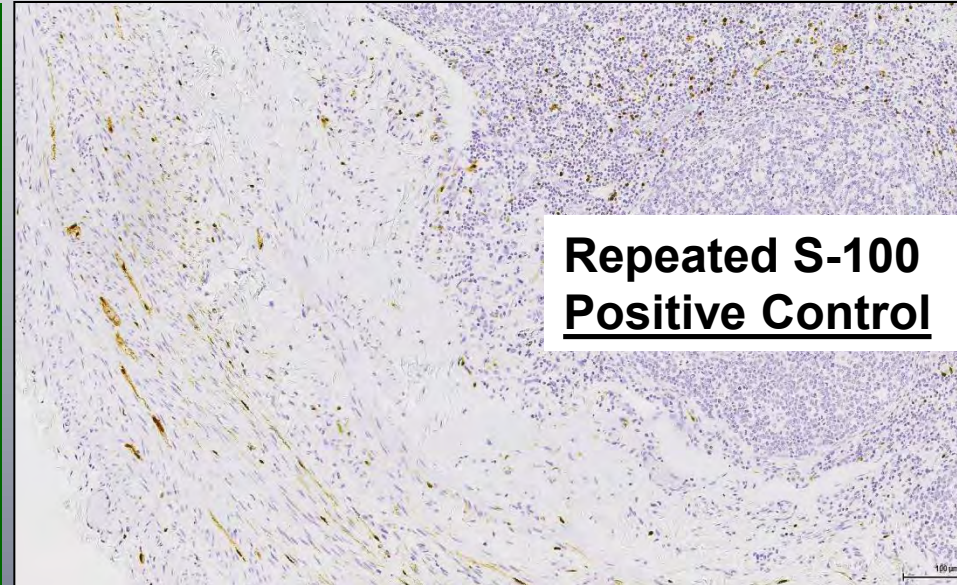
**Primary S-100
Positive Control**



Repeated S-100



**Repeated S-100
Positive Control**

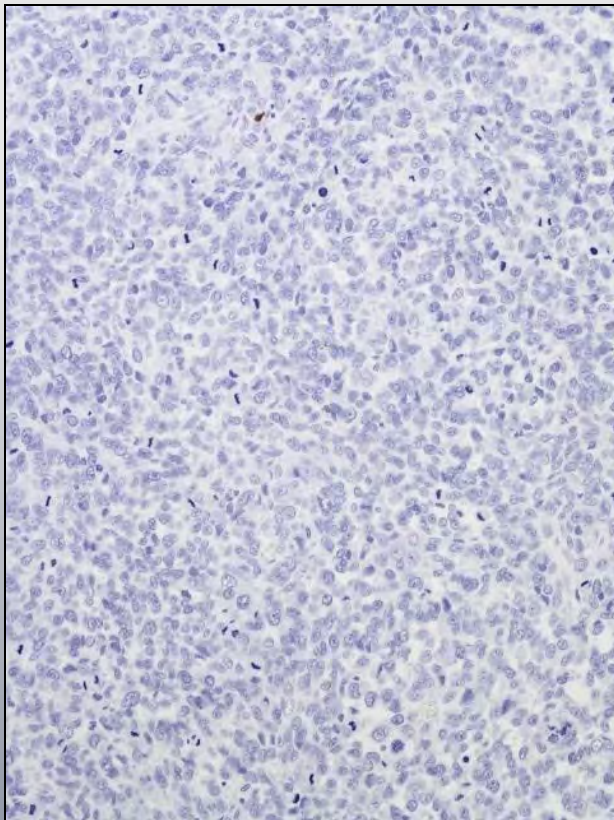


A aberrant / unexpected reactivity

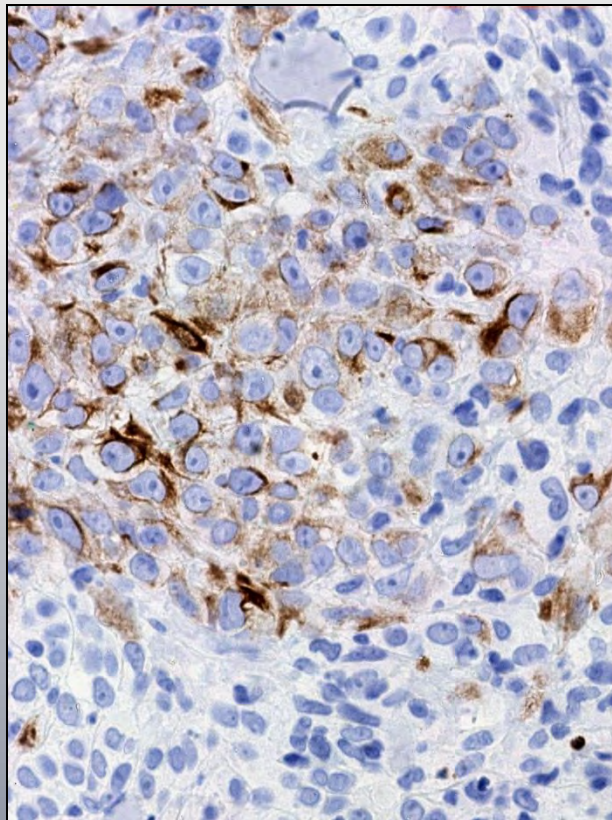
Aberrant or unexpected antigen expression / crossreactivity may be challenging especially in cases with limited antibody panel.

A aberrant antigen expression in malignant melanoma

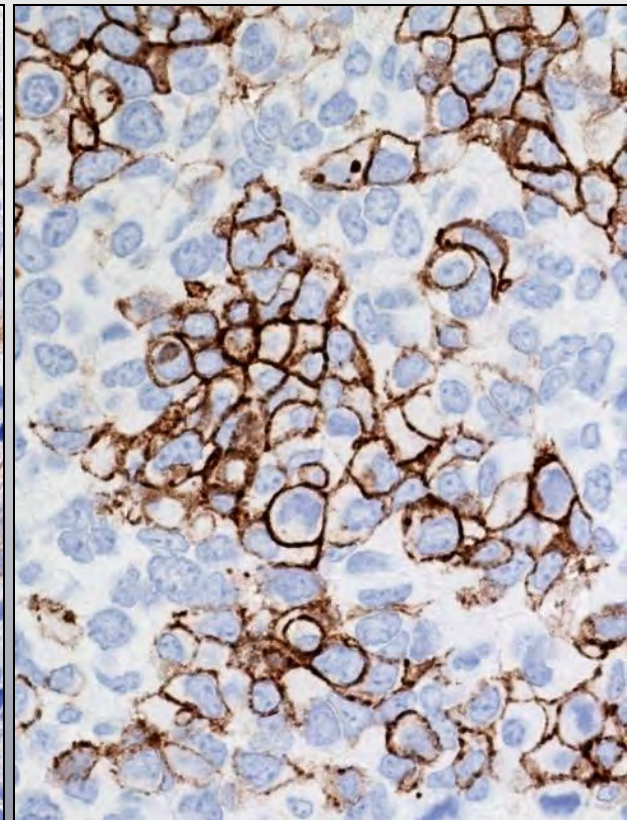
S-100



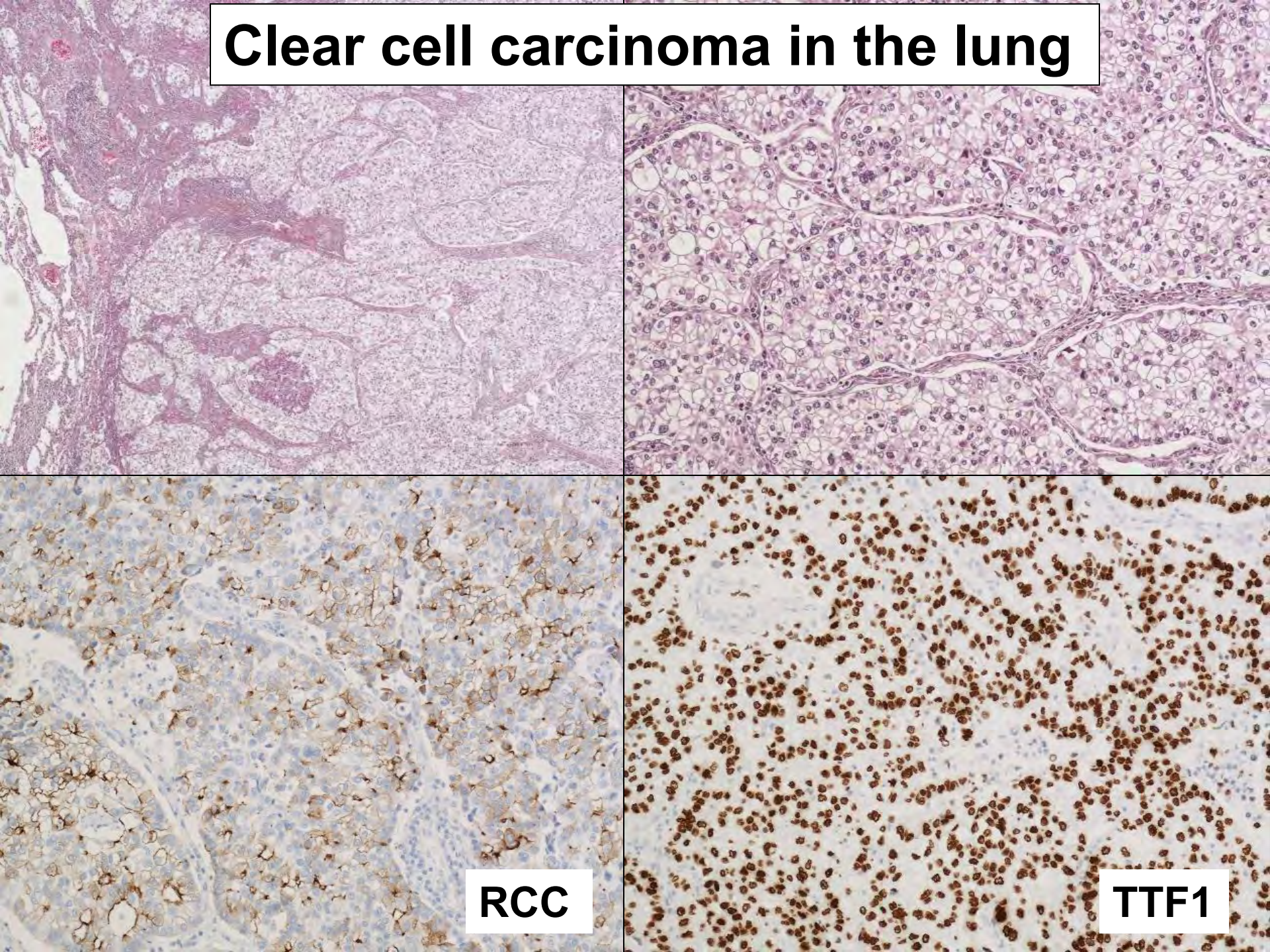
PANCK



CD45

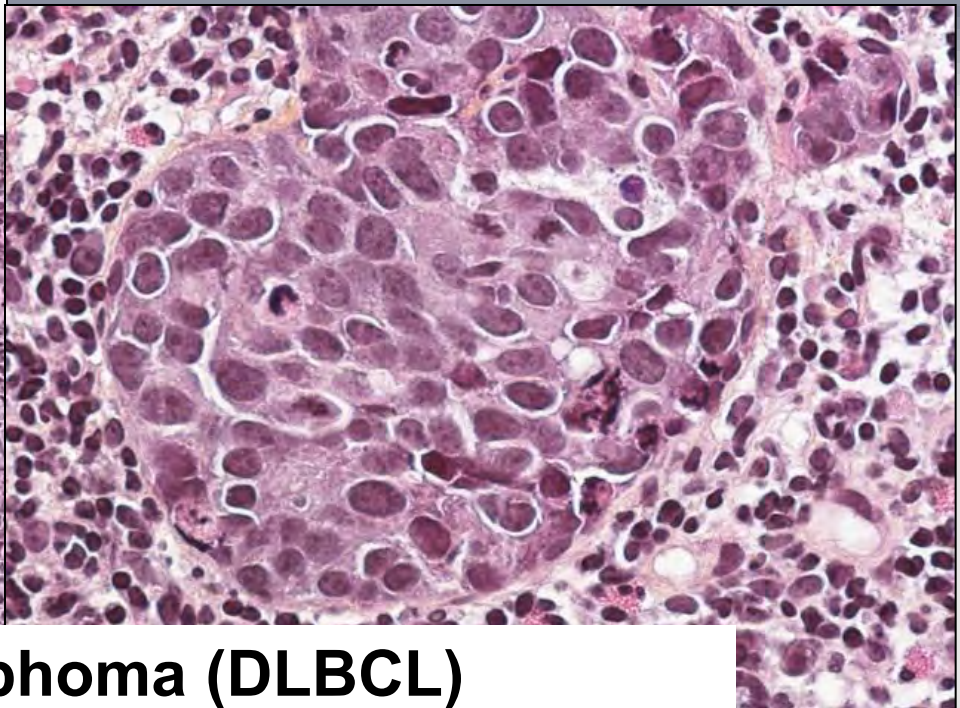
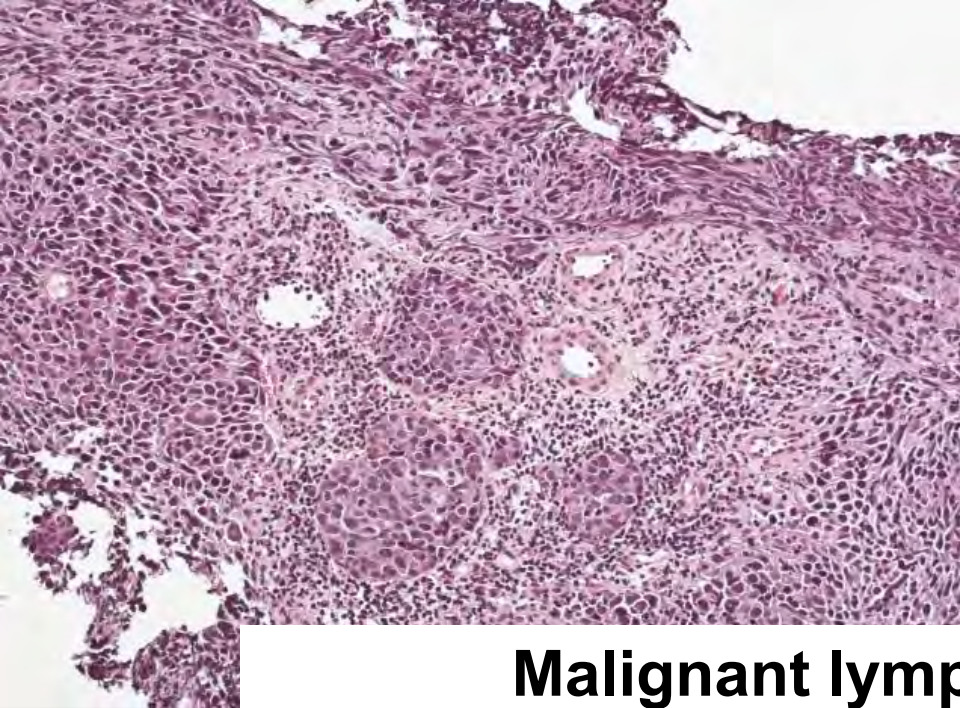


Clear cell carcinoma in the lung

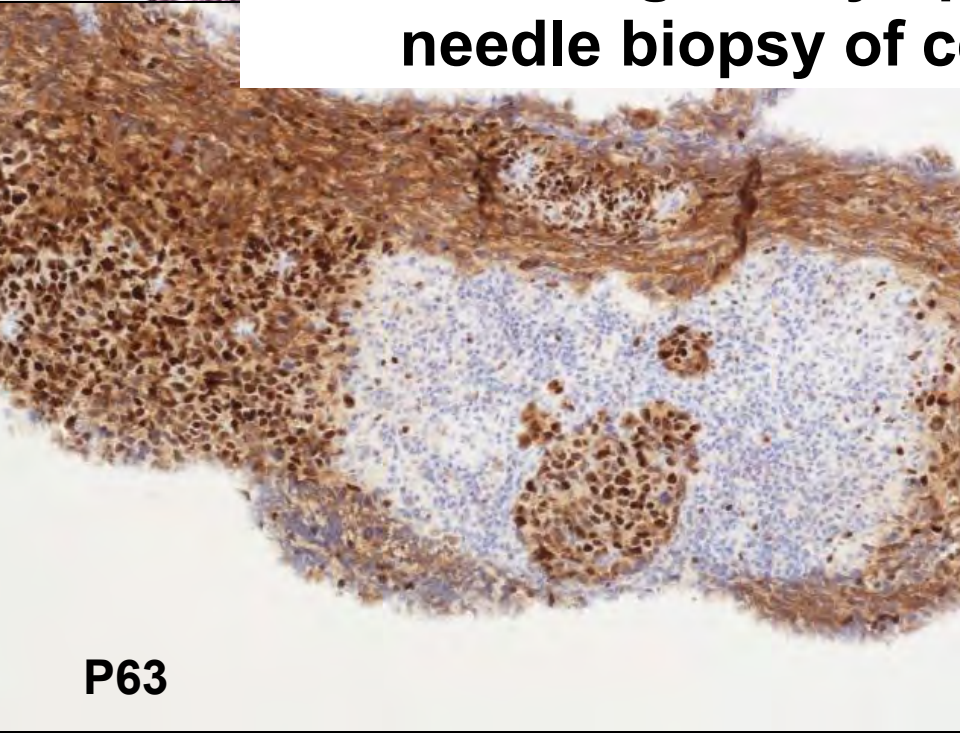


RCC

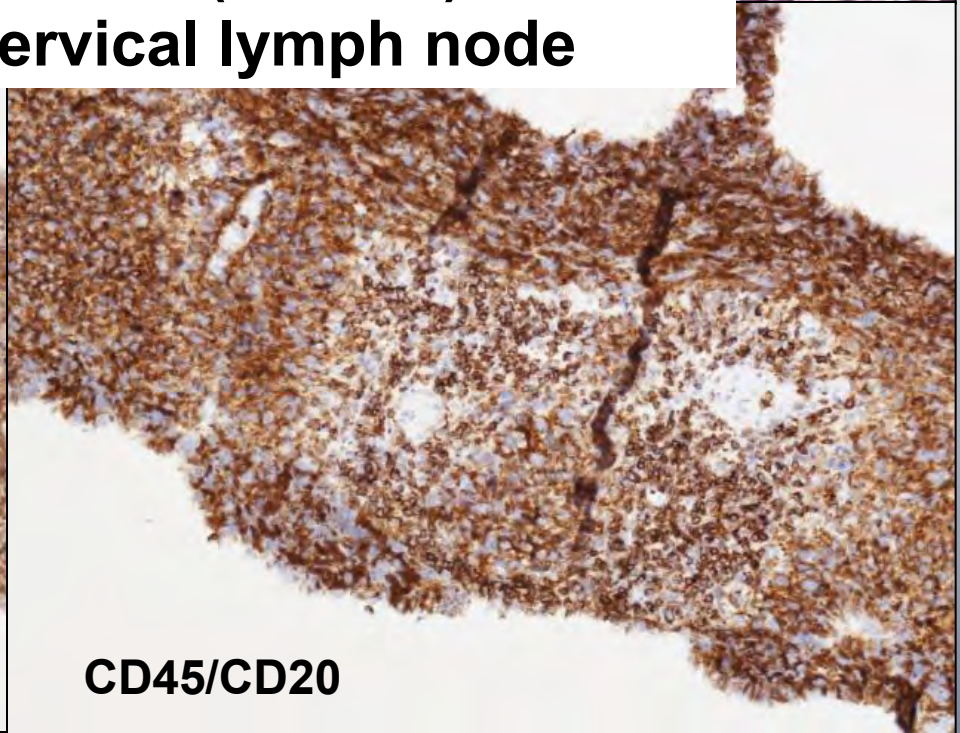
TTF1



**Malignant lymphoma (DLBCL)
needle biopsy of cervical lymph node**

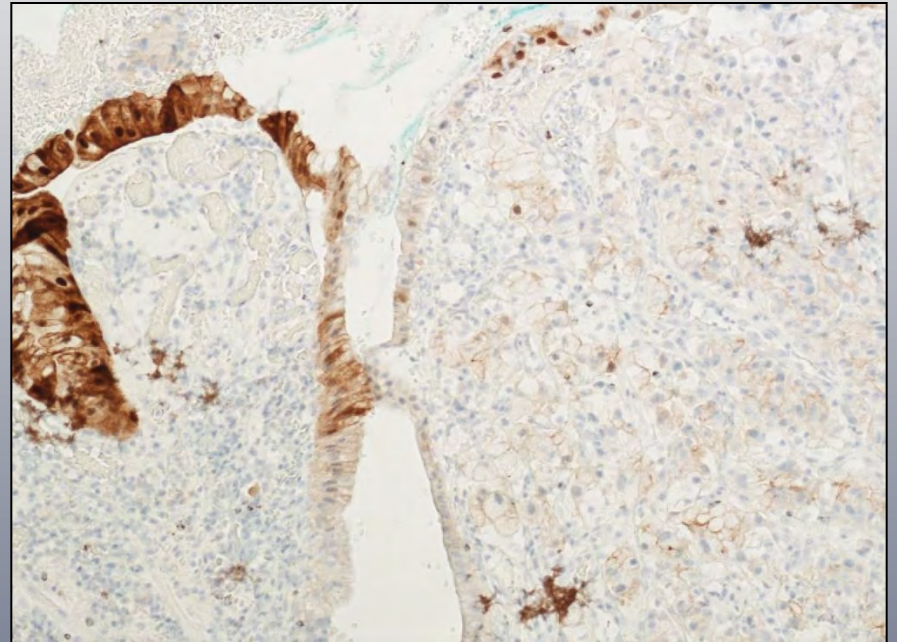
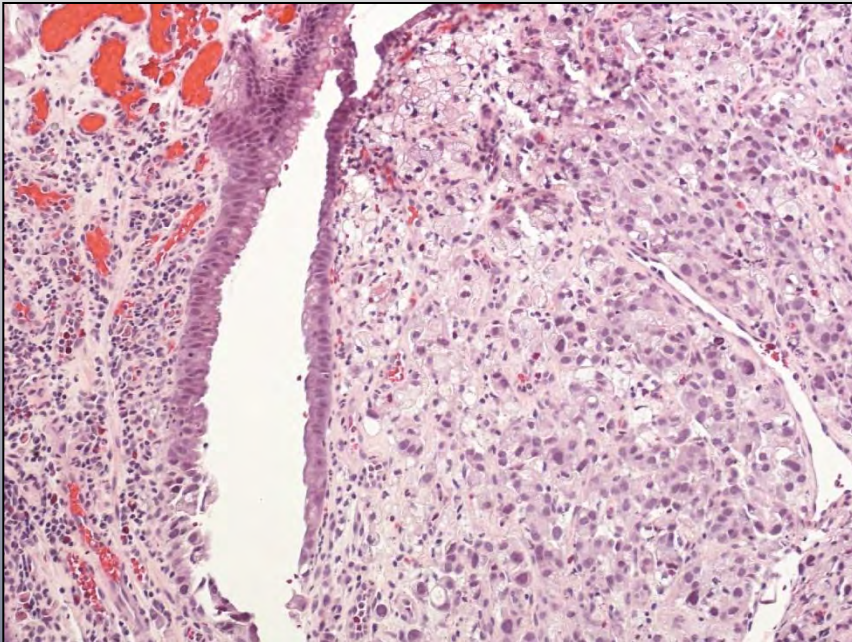
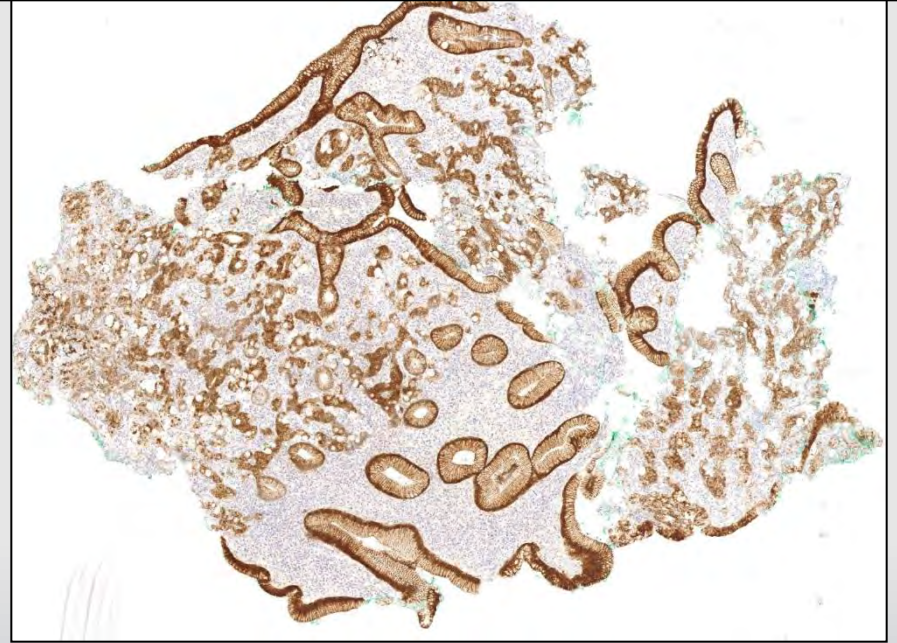
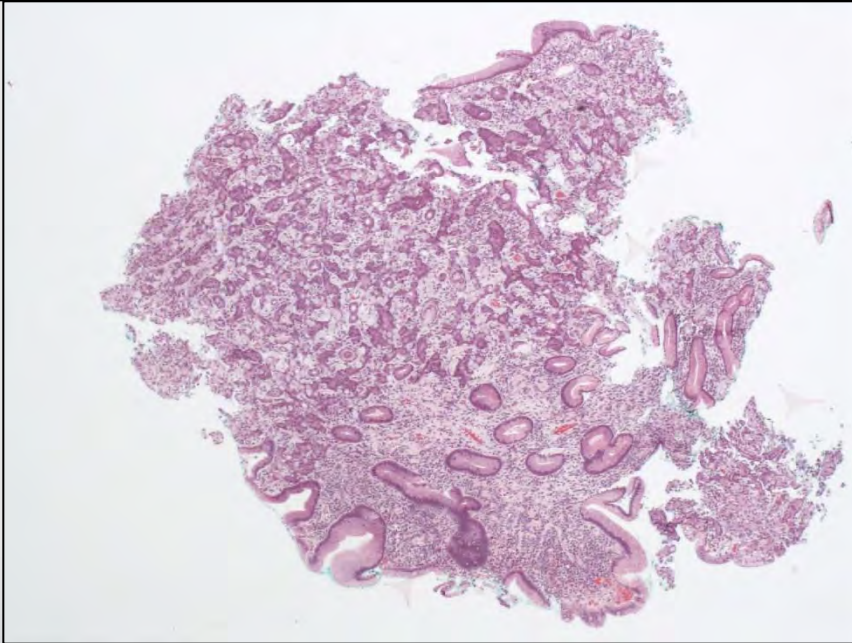


P63



CD45/CD20

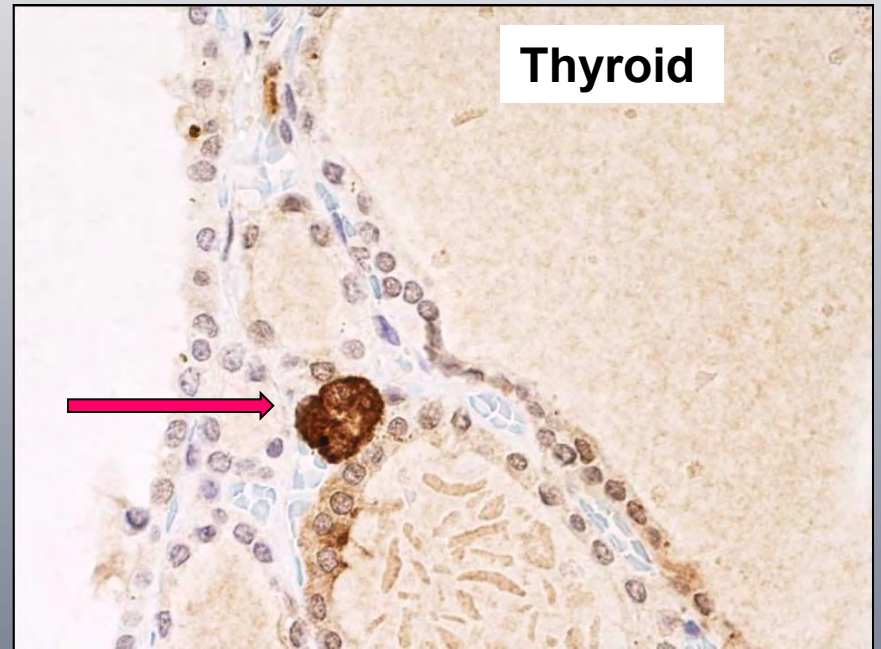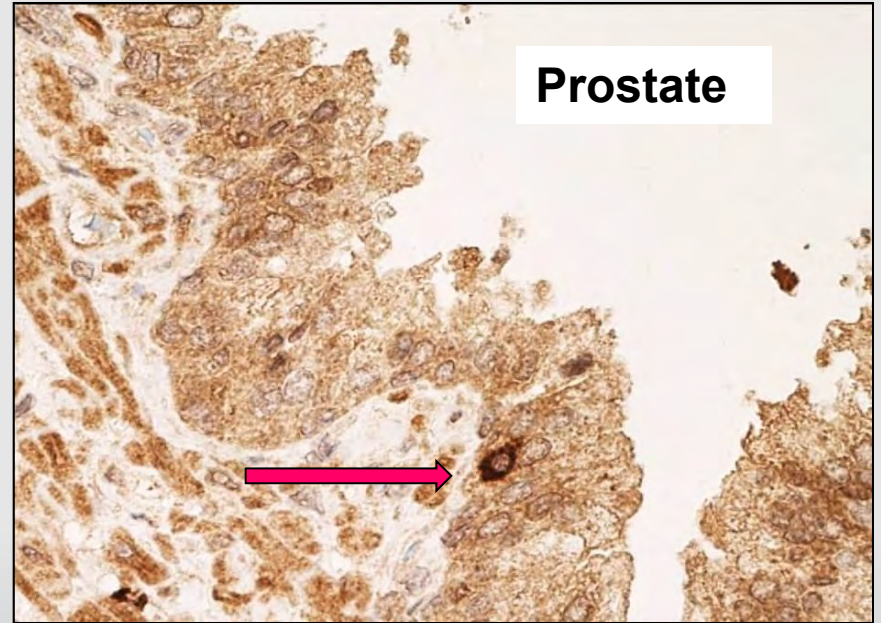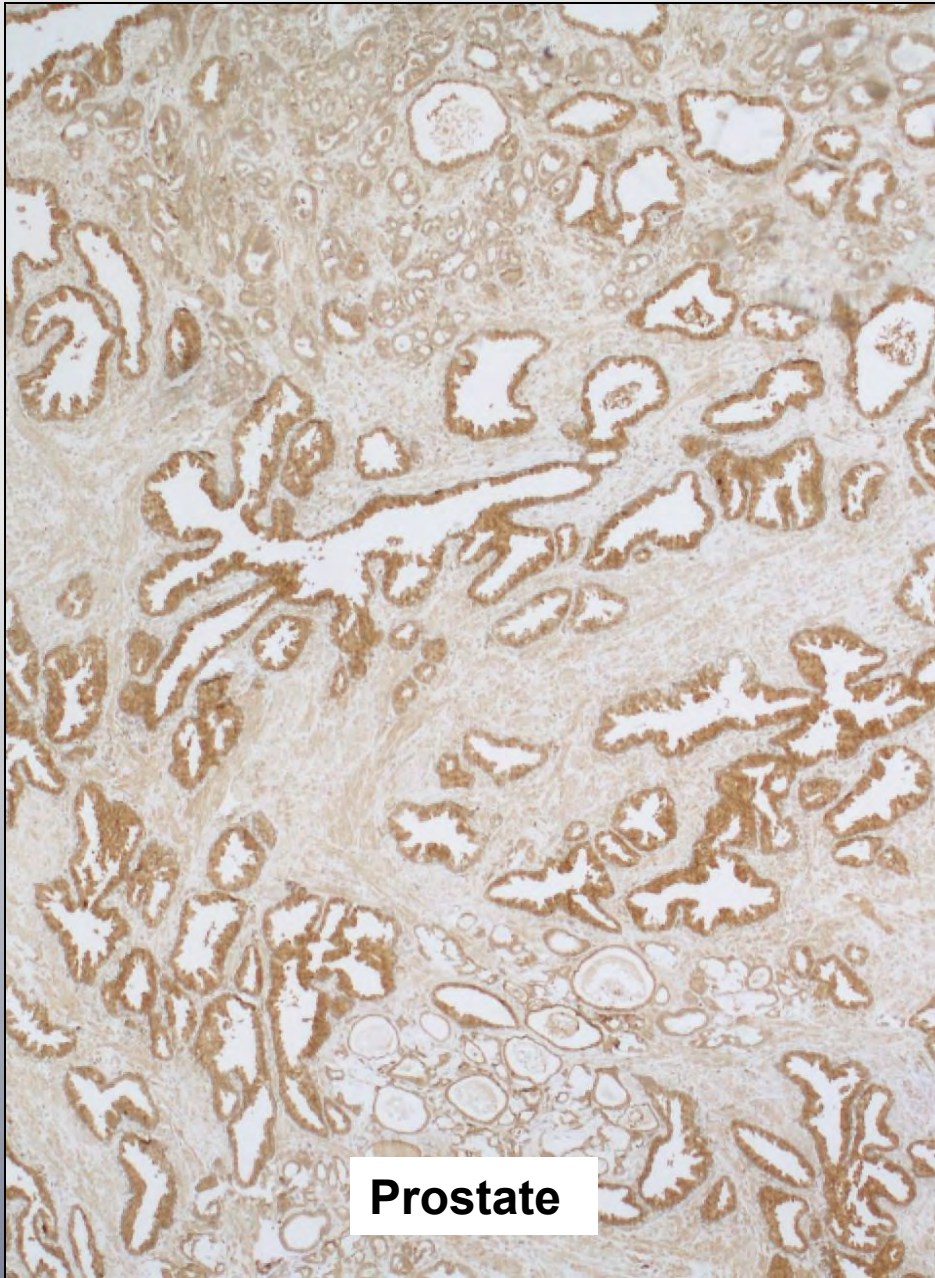
Gastric adenocarcinoma- Her2- Pathway RTU clone 4B5



Structures stained

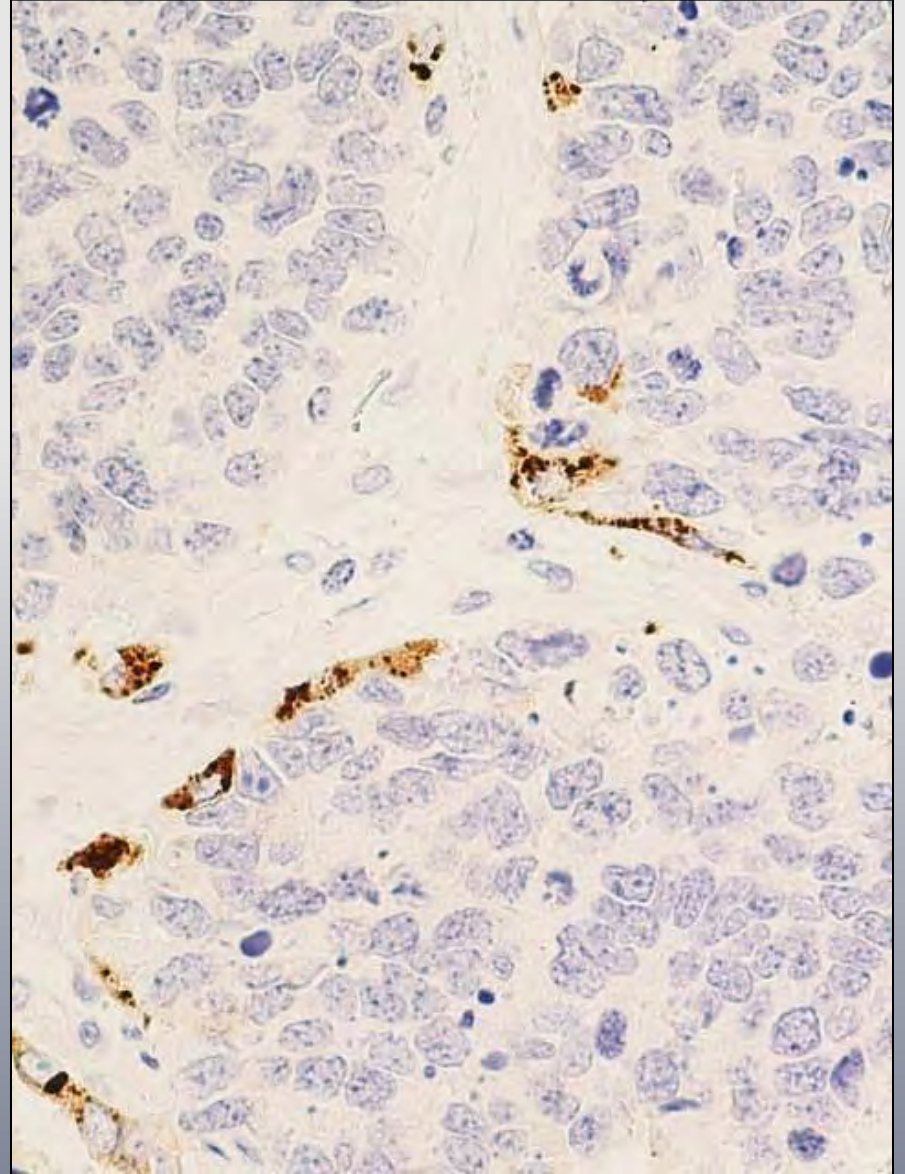
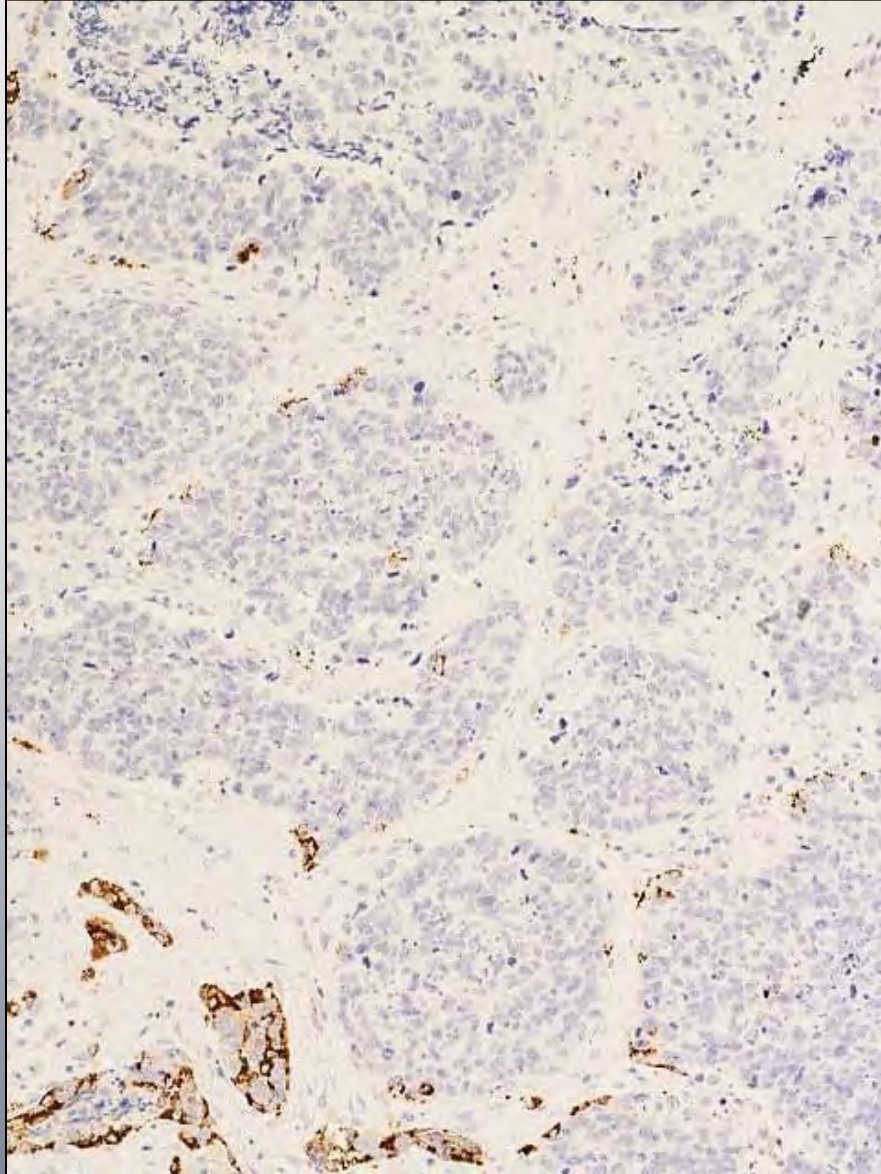
Immunoreactivity has to be localized at appropriate structures.

Calcitonin staining

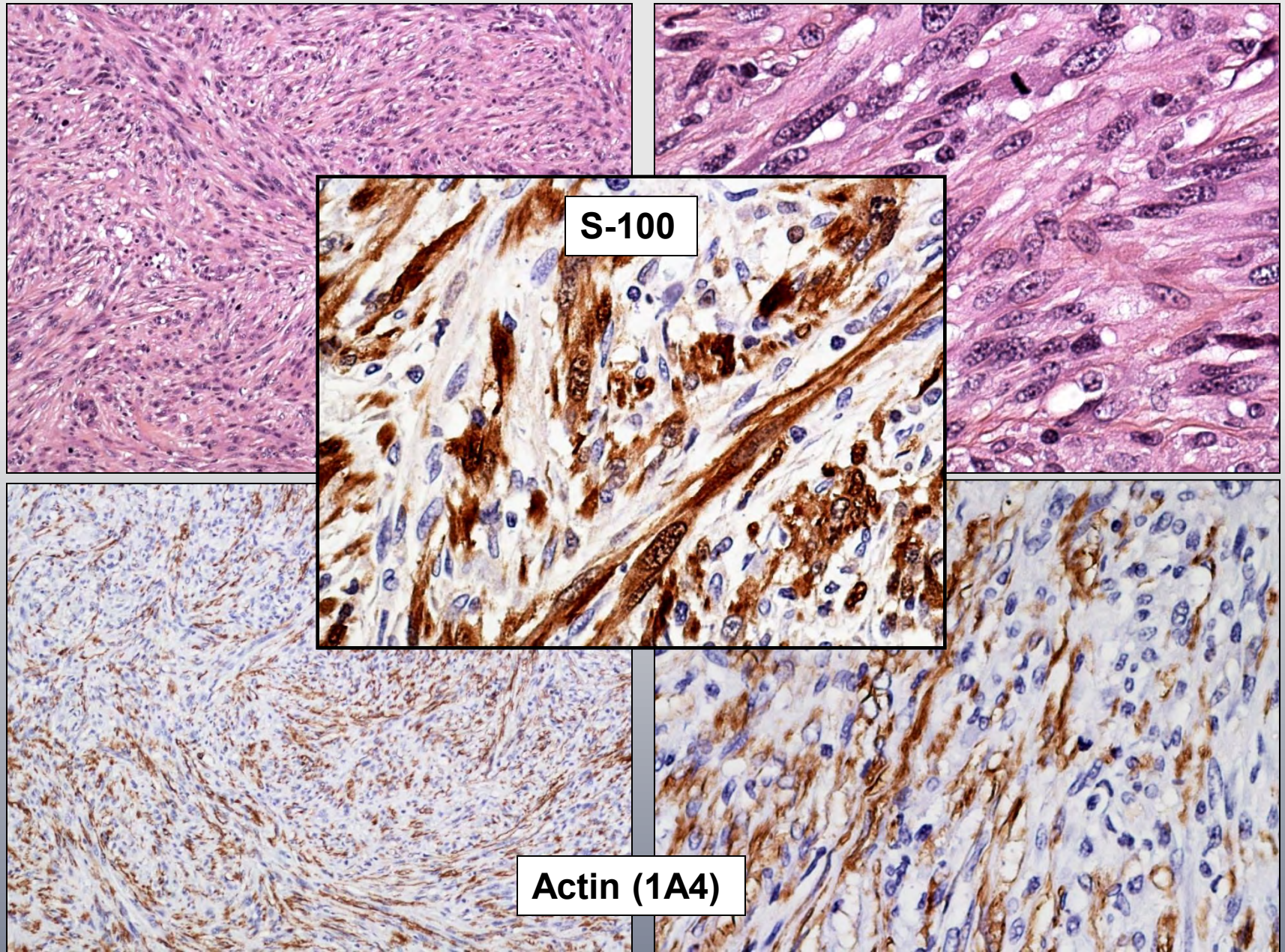


Napsin A

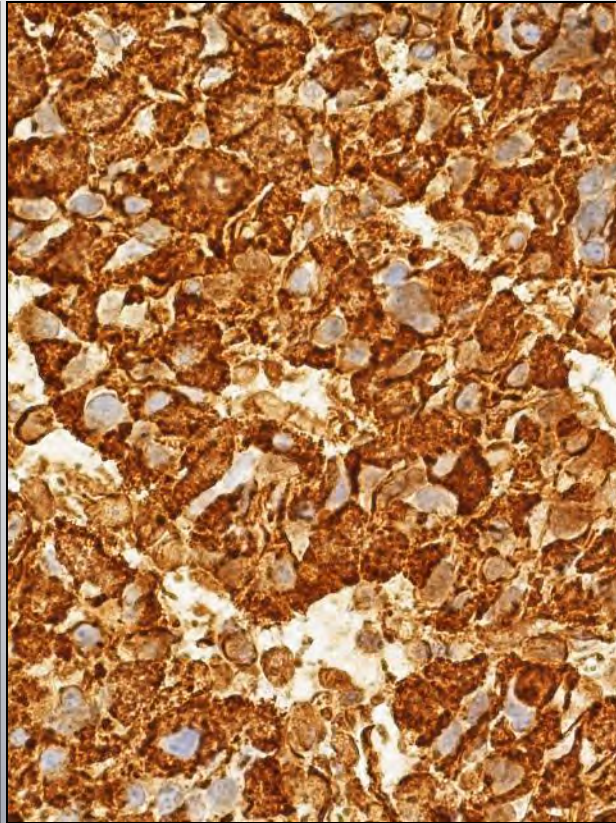
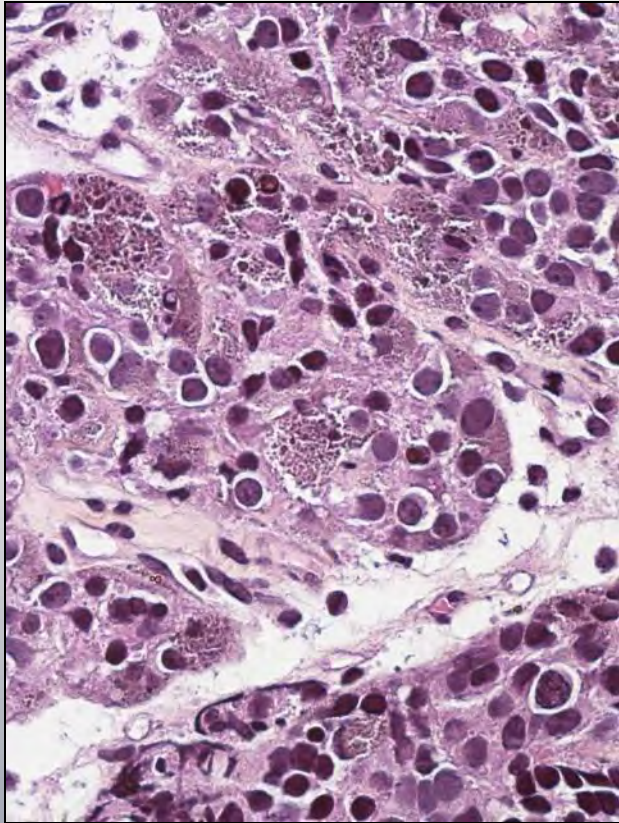
in small cell carcinoma of the lung



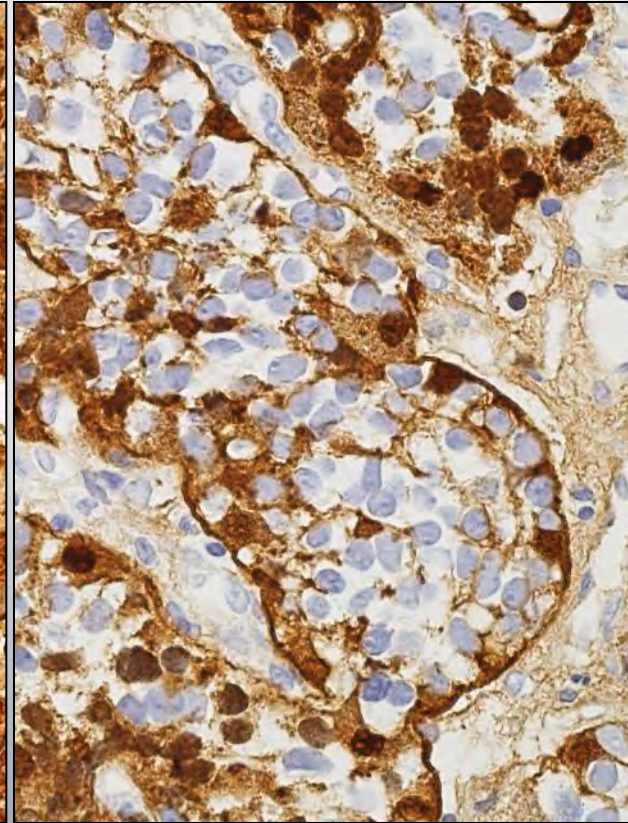
Metastatic spindle cell melanoma with Actin (1A4) positive myofibroblasts



Pigmented esthesioneuroblastoma

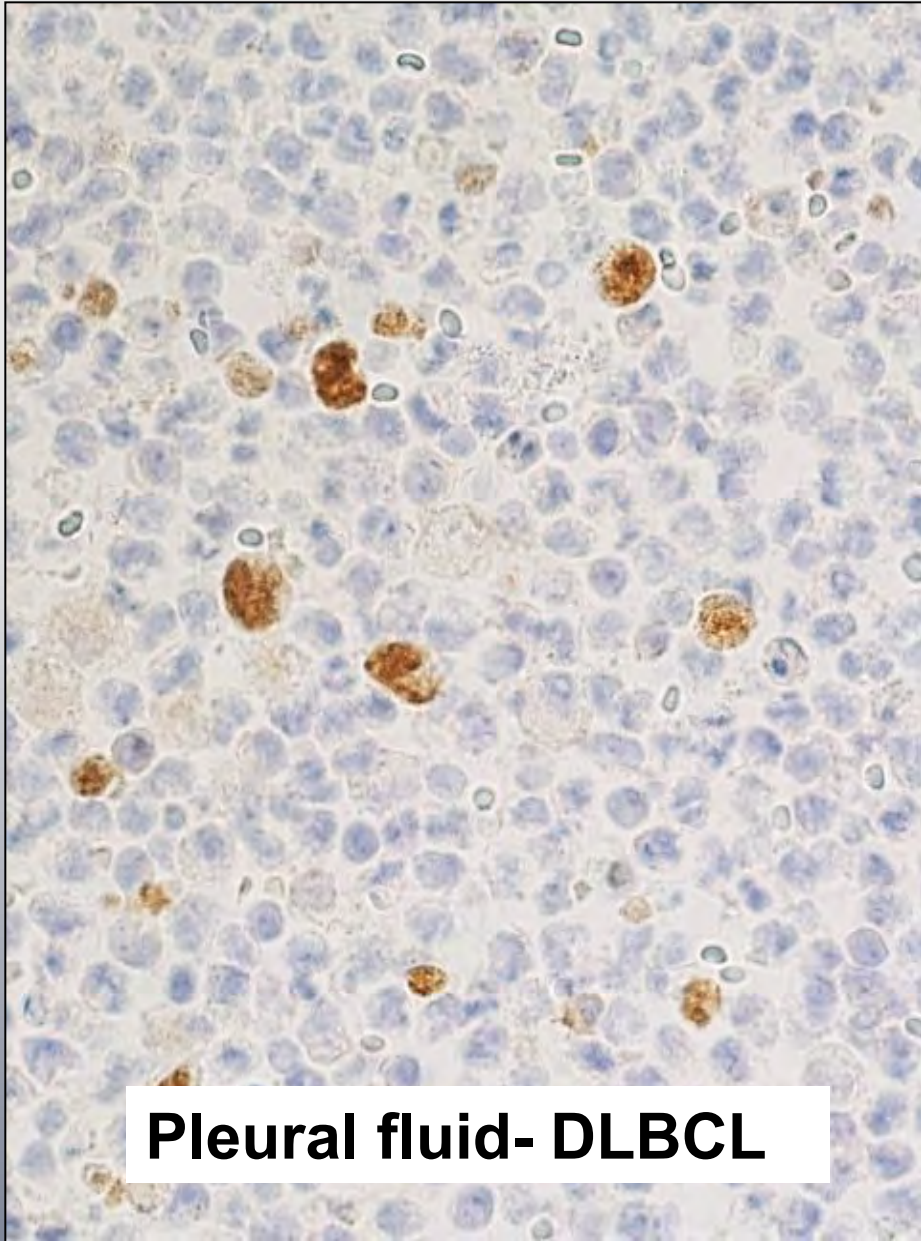


Vimentin



S-100

P63 in Lymphoma and striated muscle

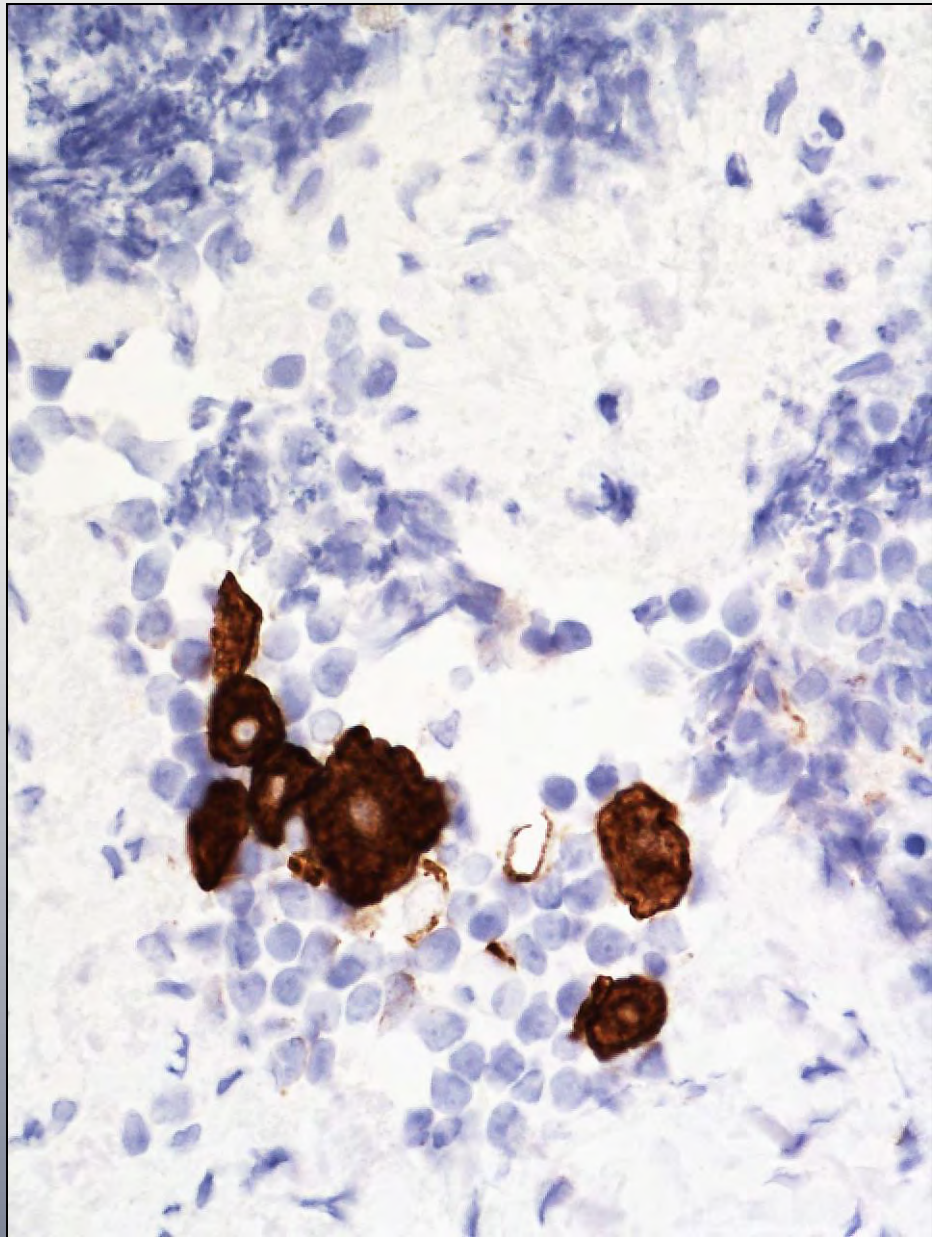
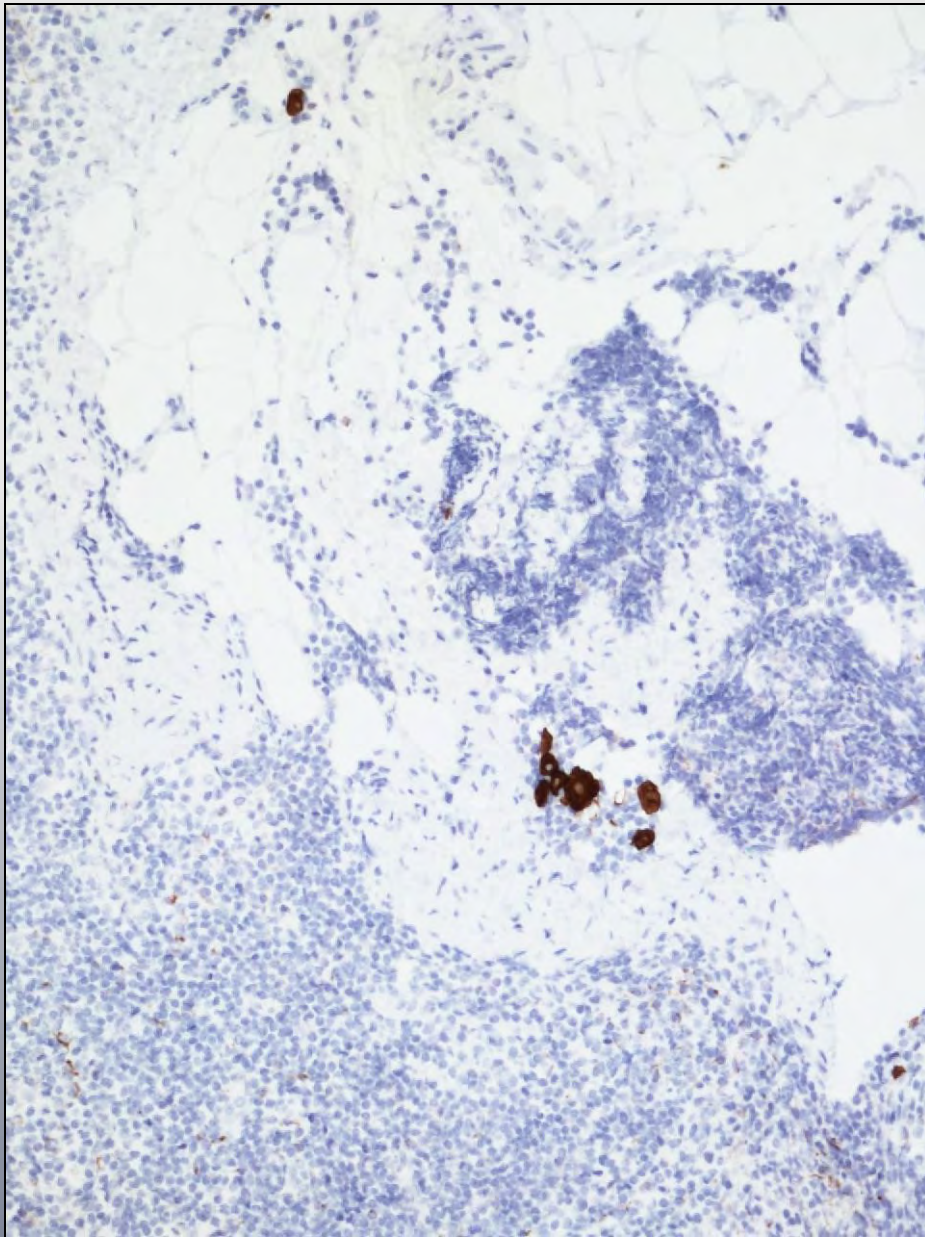


Pleural fluid- DLBCL



Striated muscle

PAN-CK in sentinel node - floater



Lung biopsy diffuse lesion

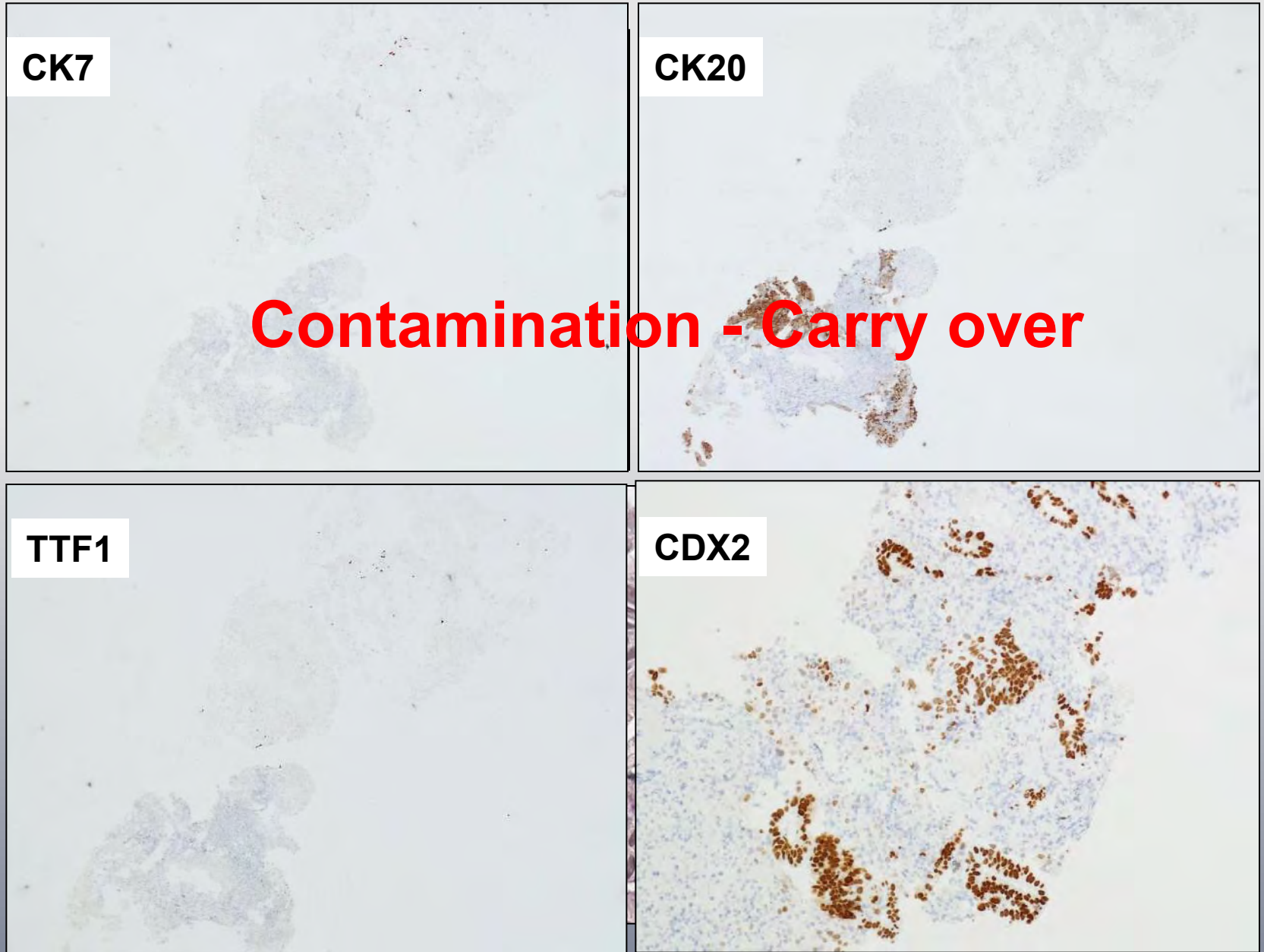CK7

CK20

Contamination - Carry over

TTF1

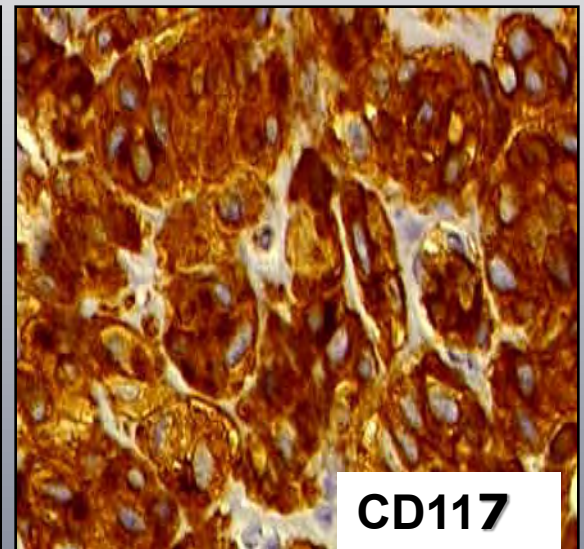
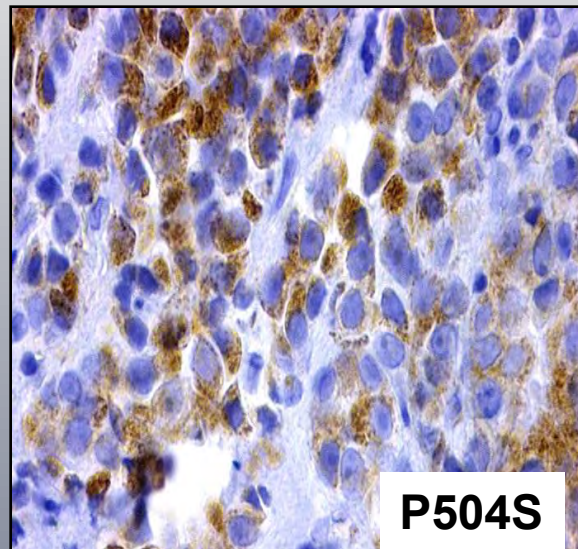
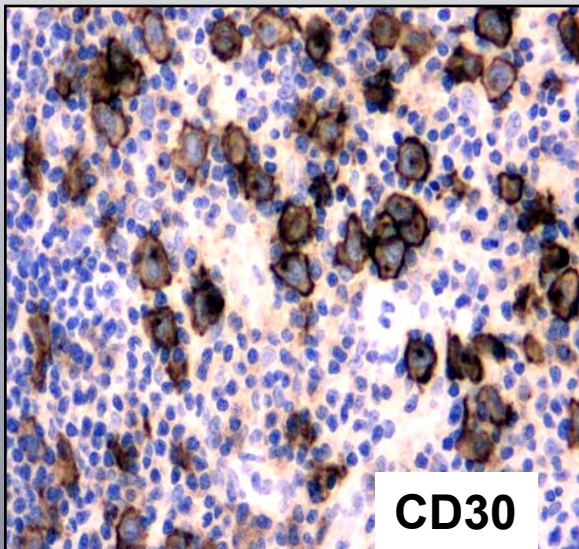
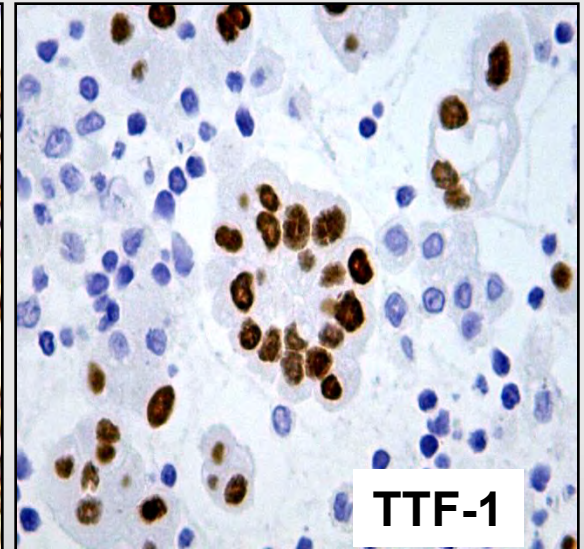
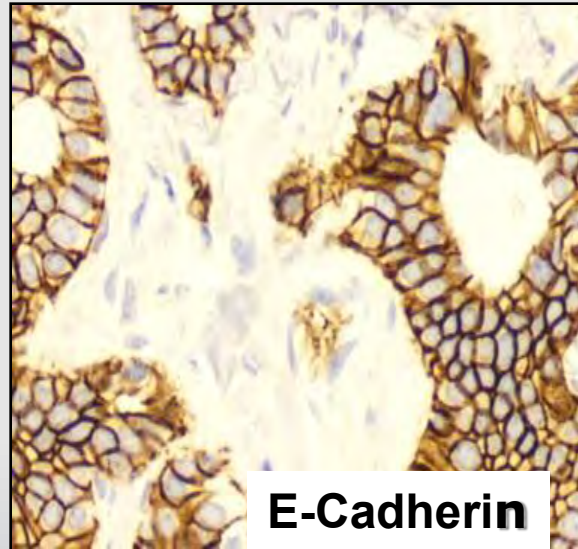
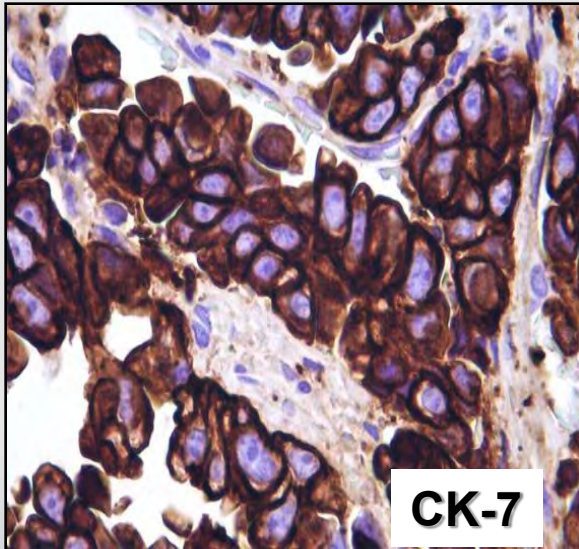
CDX2



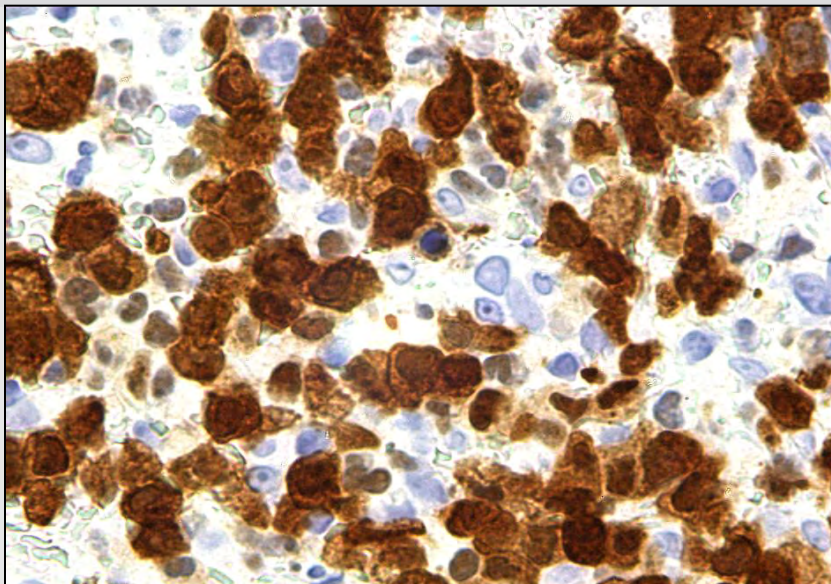
Pattern of staining

The pattern of staining and localization in the cellular compartment should be appropriate for the antigen.

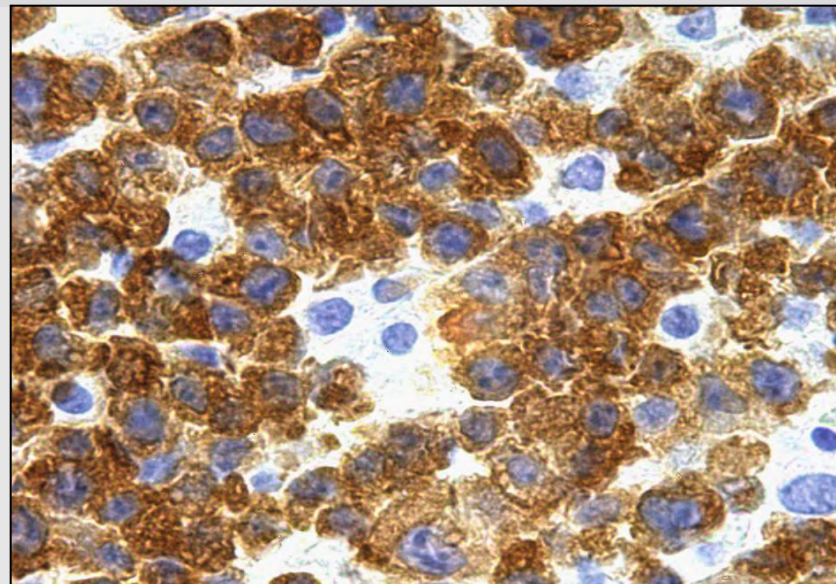
Spectrum of staining patterns



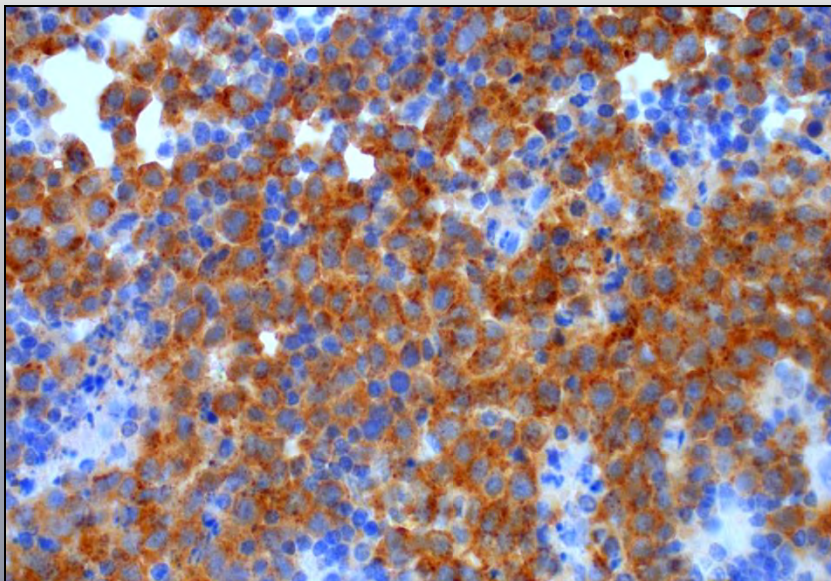
ALK staining (ALK-1)



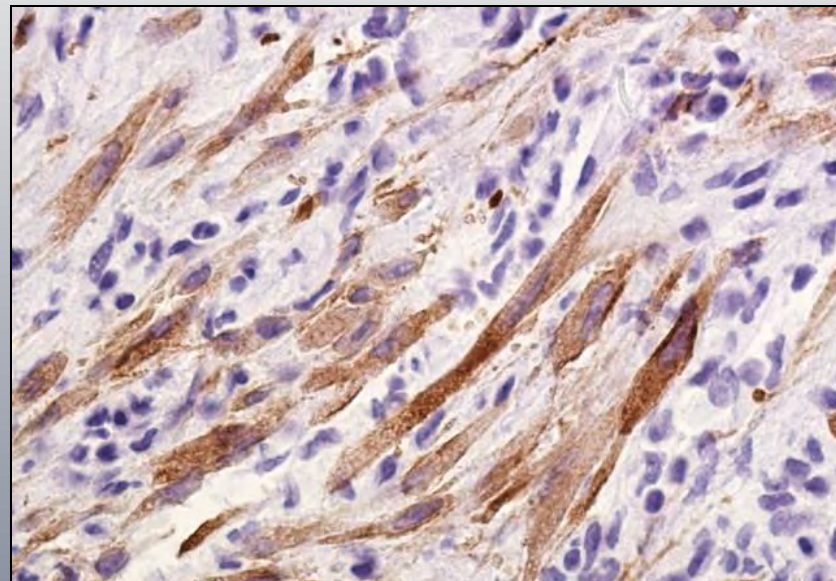
Anaplastic Large Cell Lymphoma with t(2;5)



Anaplastic Large Cell Lymphoma with t(1;2)

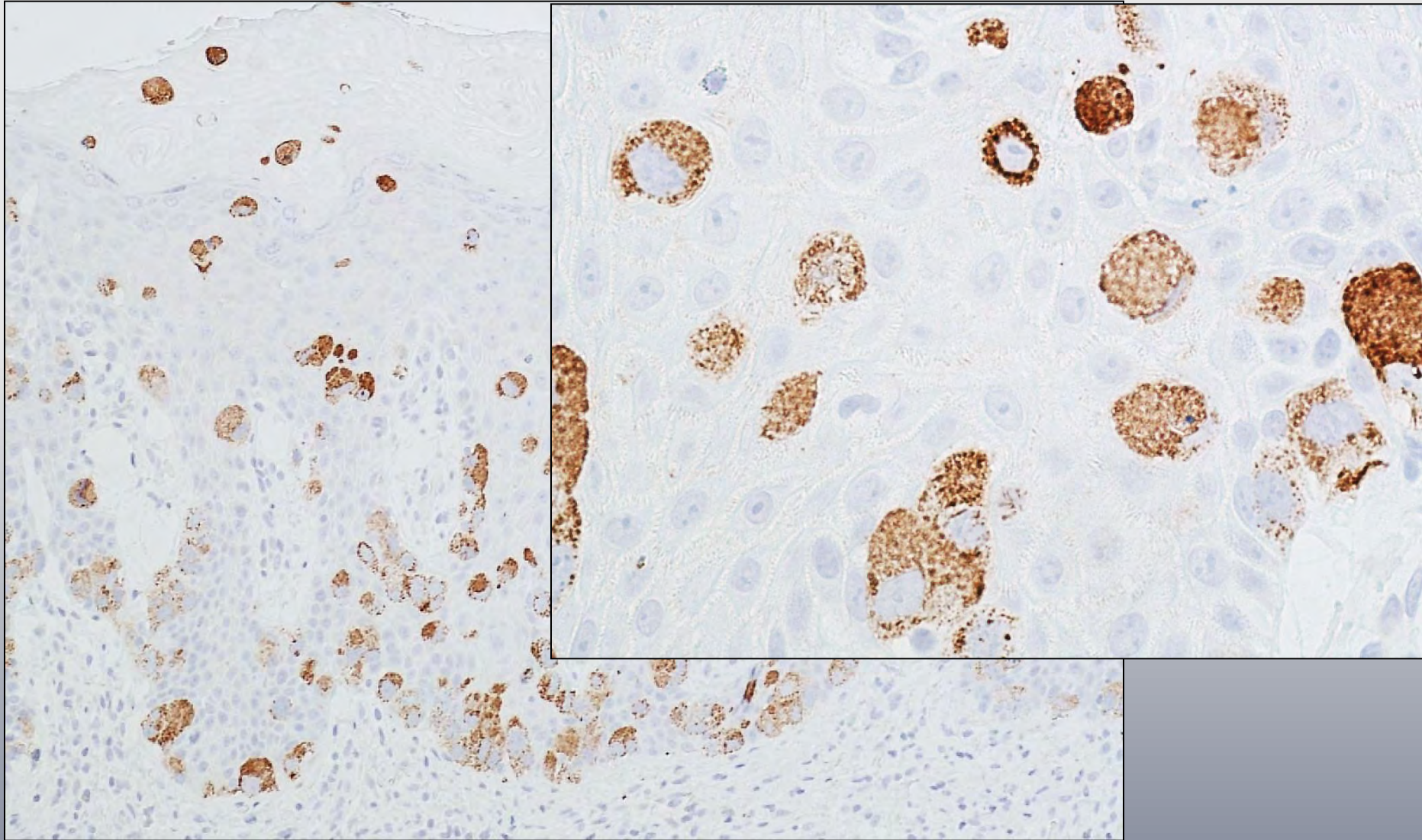


ALK+ Large B-Cell Lymphoma with t(2;17)
(courtesy of W. Klapper, Kiel)

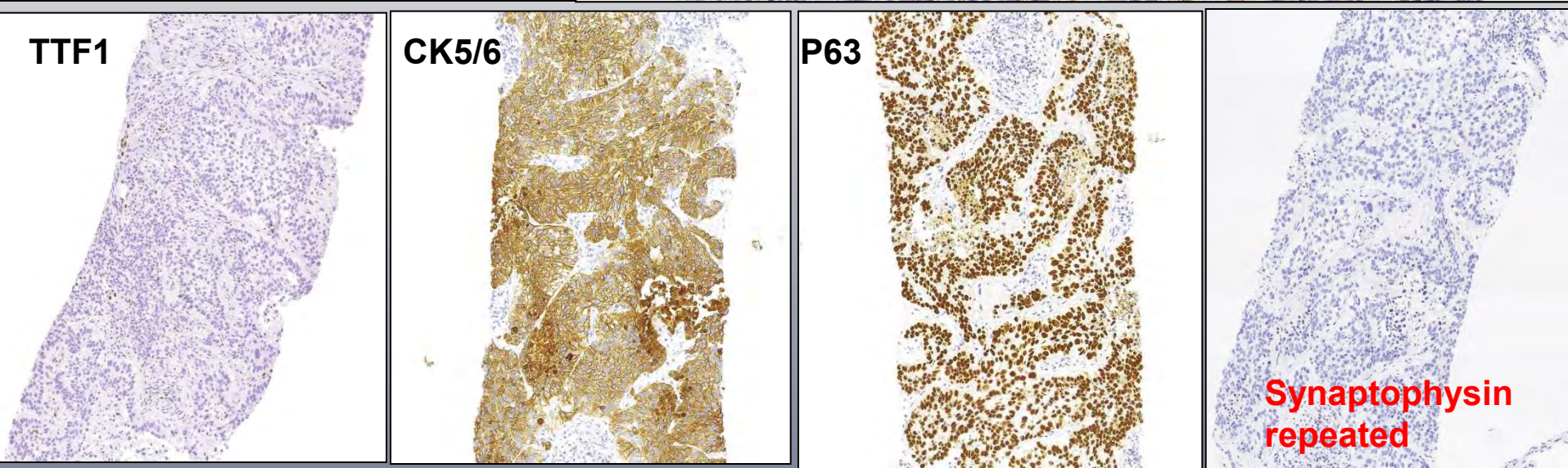
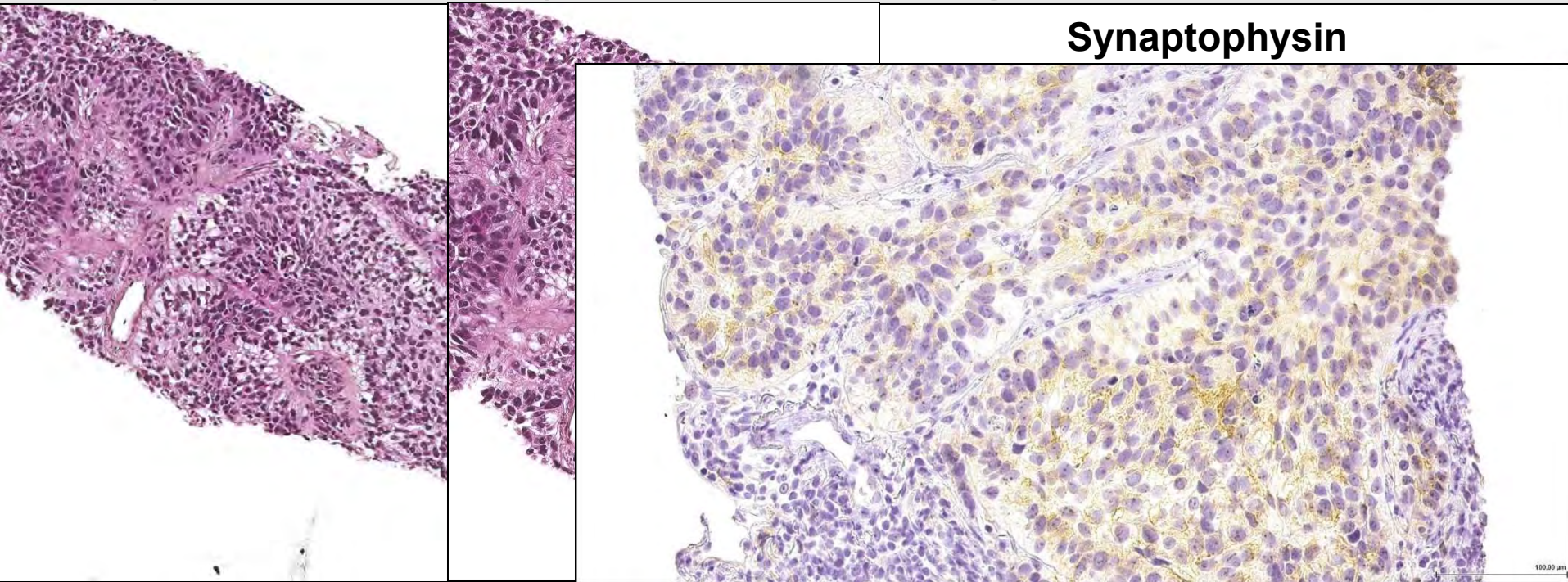


**Inflammatory myofibroblastic tumour
with t(1;2)**

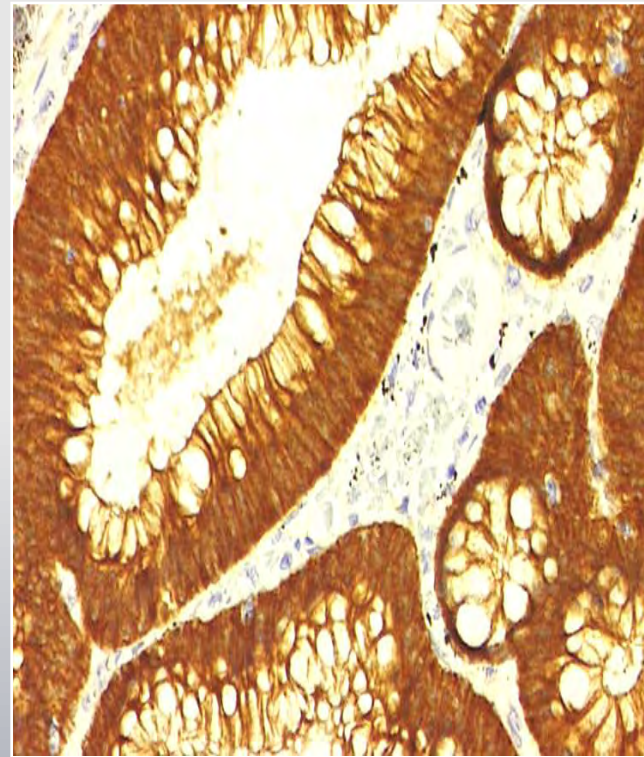
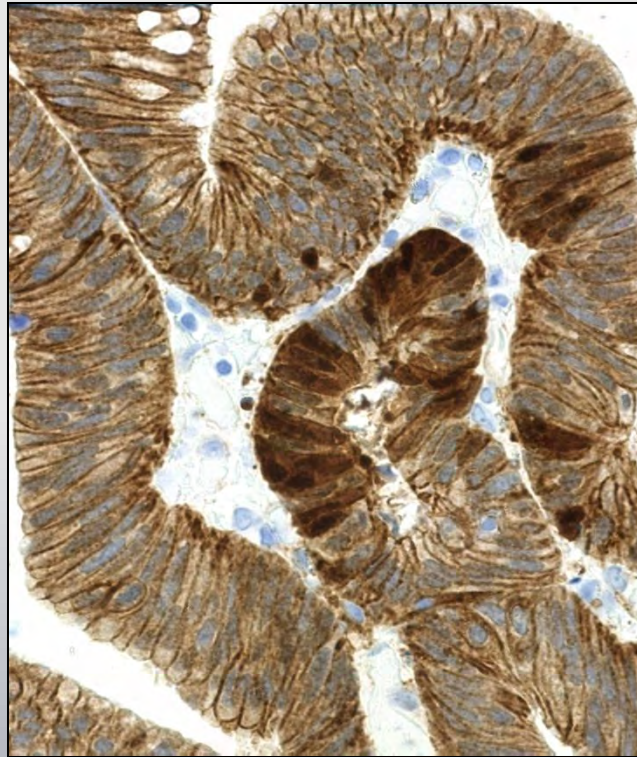
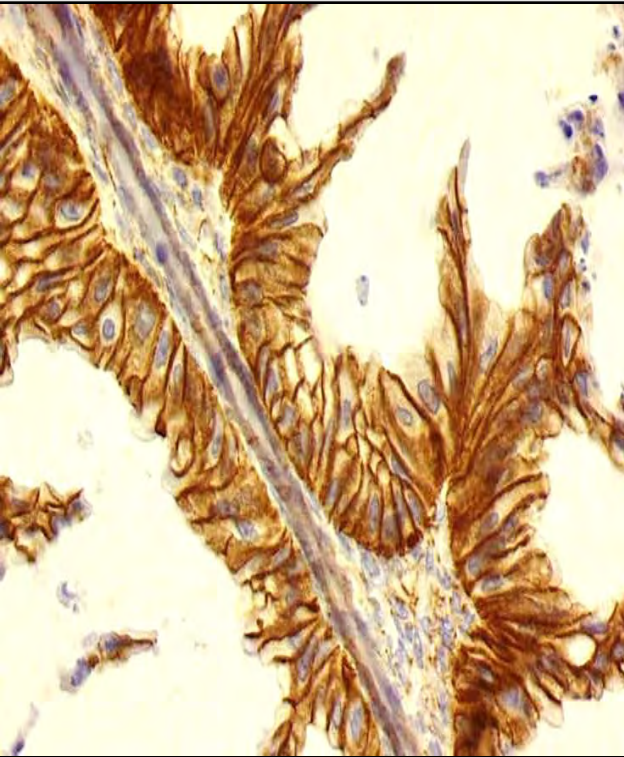
Extramammary Paget – Herceptest



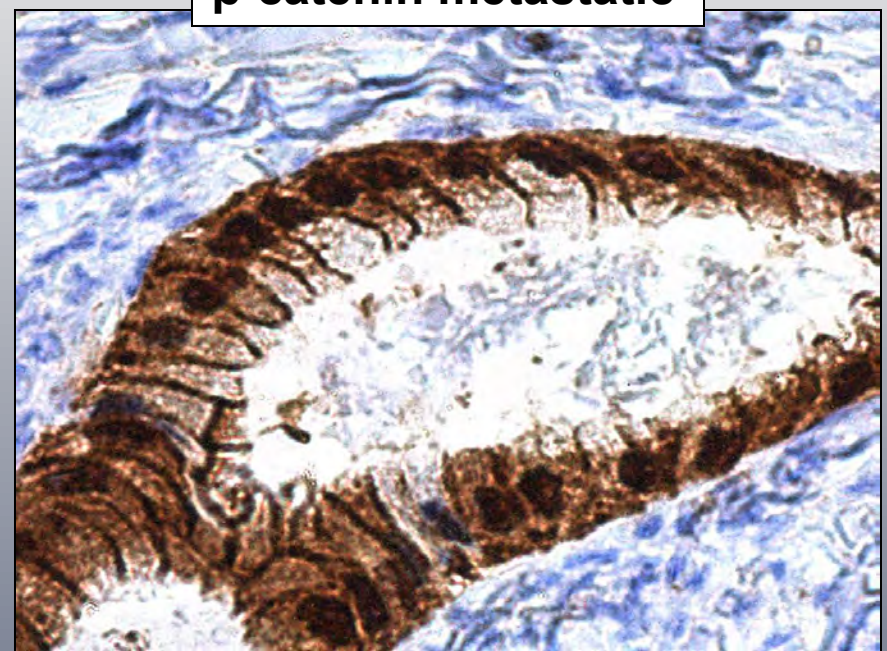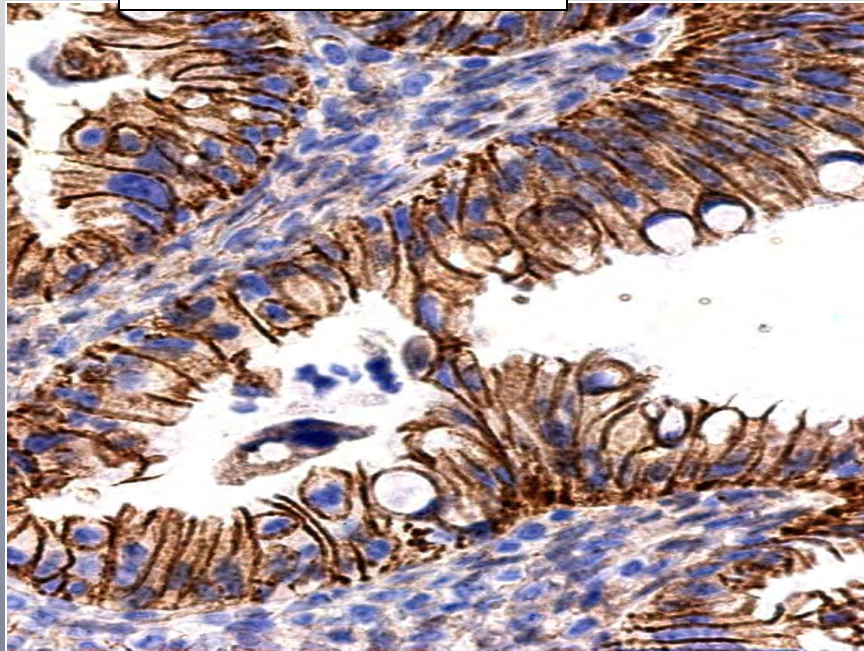
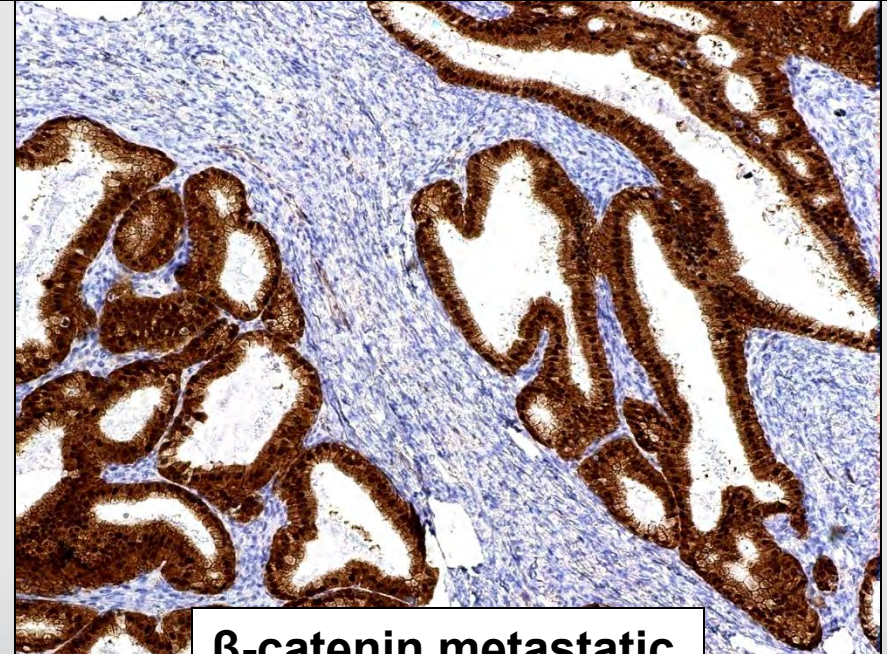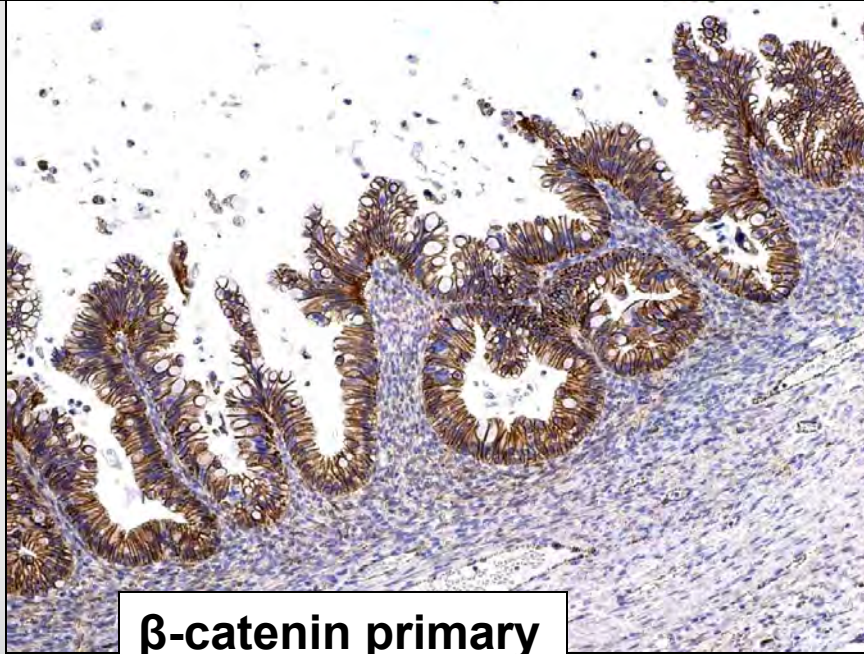
Synaptophysin in lung carcinoma



β -catenin in colon adenoma



Mucinous primary adenocarcinoma in ovary vs. metastatic colorectal

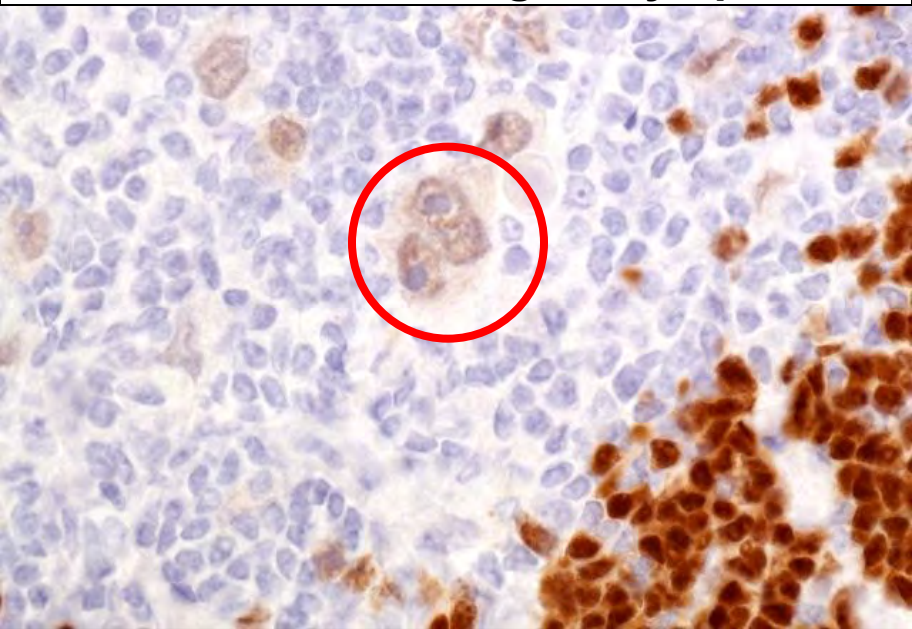

Intensity of staining

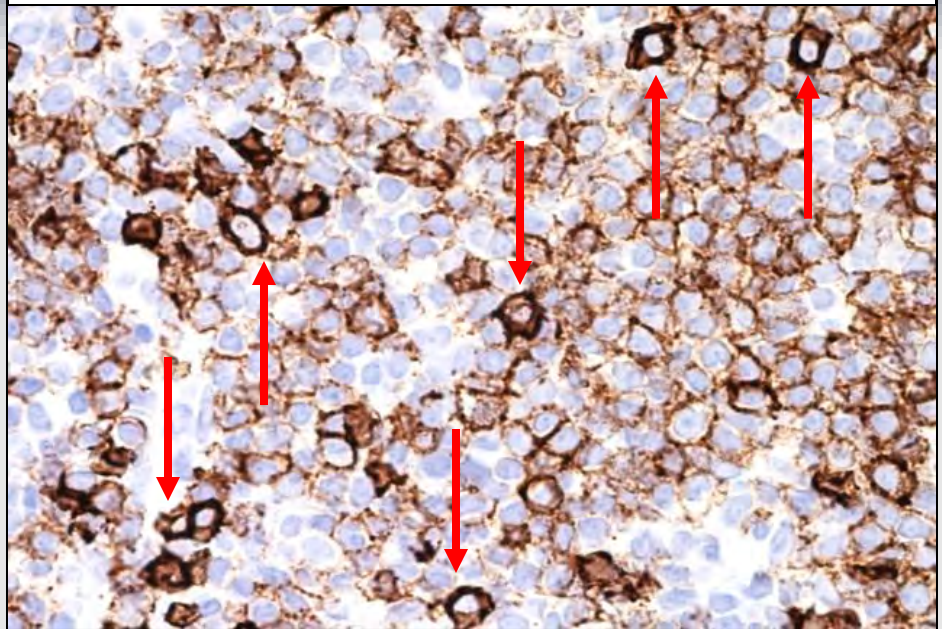
May vary depending on performance of the laboratory, biology of the tumour and analyzed sample

In some cases the intensity of staining may provide important diagnostic information

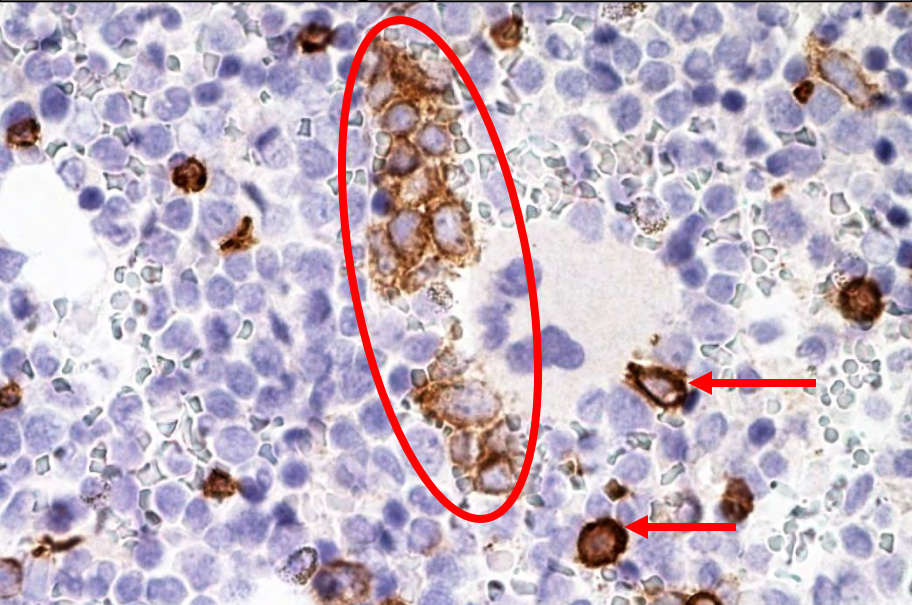
Weak PAX5 in c-Hodgkin Lymphoma



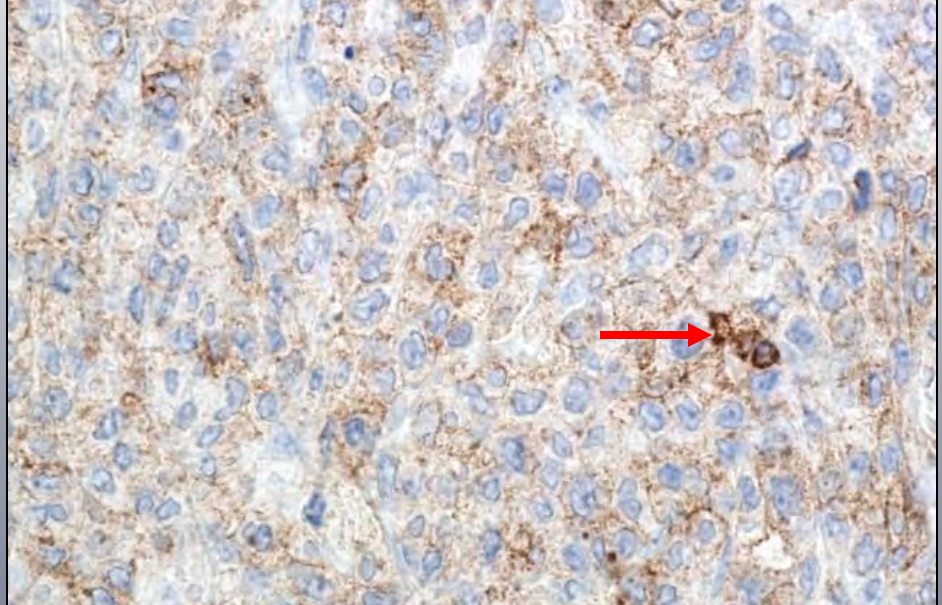
Weak CD20 in B-CLL



Weaker CD3 in Hepatosplenic T-cell Lymphoma



Weak CD4 in myeloid sarcoma with monocytic differentiation



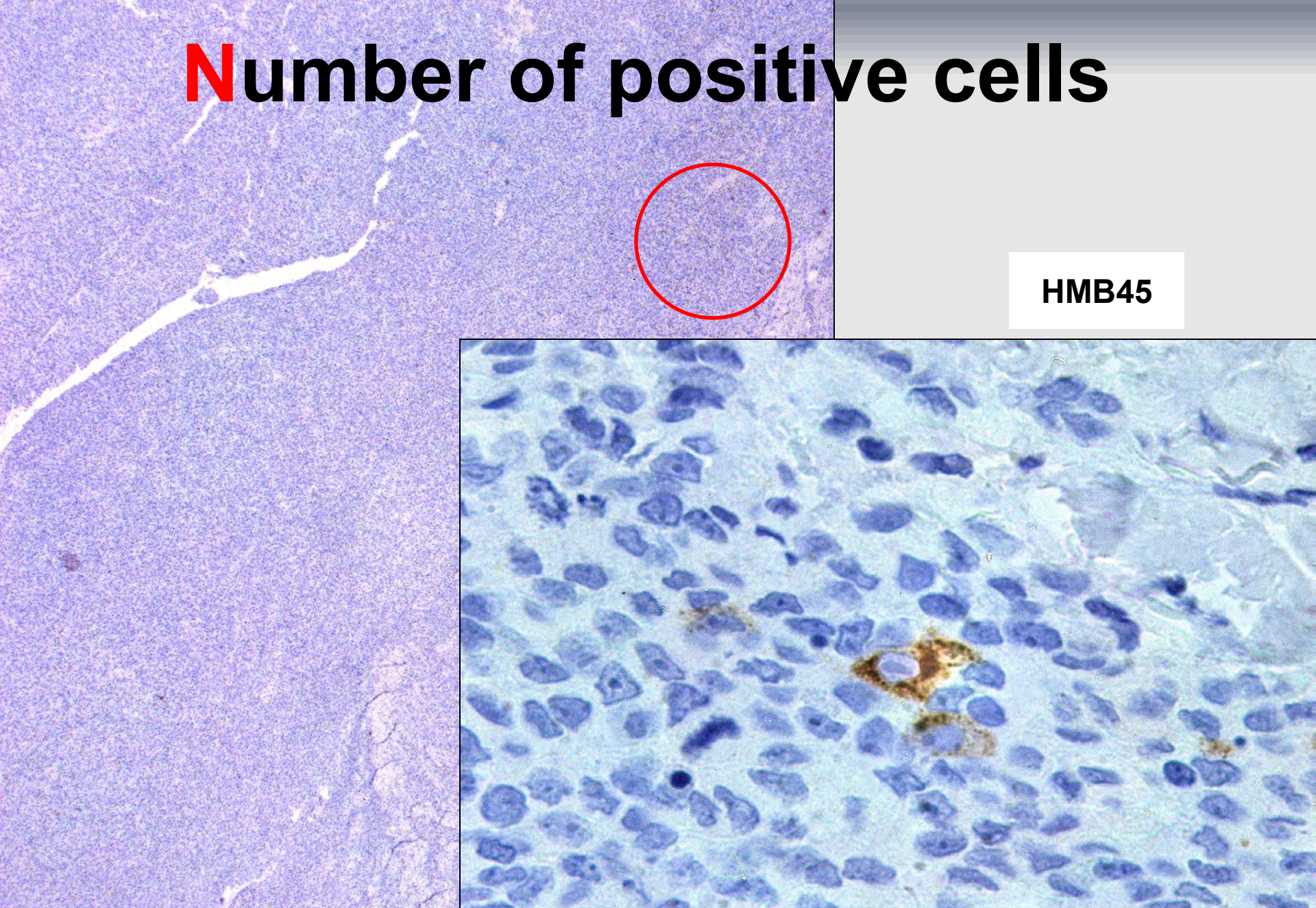
Number of positive cells

Difficult to establish arbitrarily.

Number of positive cells may vary depending on:

- biopsy size**
- biology of tumor**
- laboratory performance**

Number of positive cells



HMB45

Recurrent malignant melanoma

What is considered a positive result?

- **Intensity of staining?**
- **Any number of stained cells?**
- **5%?**
- **10%?**
- **?**

Oligobiopsy !?

Needle biopsy



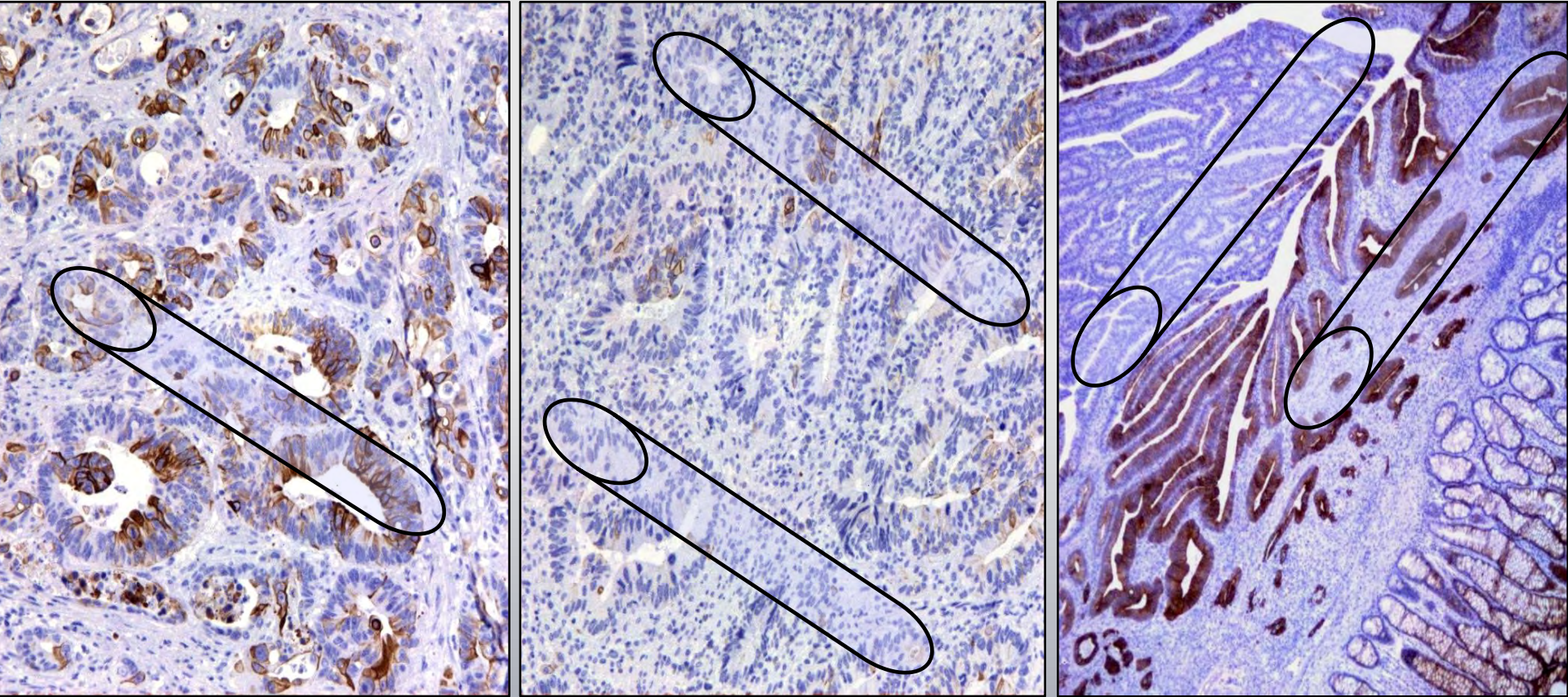
Excision biopsy



R
e
s
e
c
t
i
o
n



Colon adenocarcinoma CK-20



Should the cut off point for positive IHC staining be different for small biopsies and for large resections?

Adequate tissue block

Adequate antibody panel

Adequate antibody
clone

Adequate staining of
internal/external controls

A aberrant reactivity

Structures stained

Pattern of staining

Intensity of staining

Number
of stained cells

Dealing with unexpected results

- Check staining of appropriate external and internal tissue controls
- Correlate IHC results with morphology and detailed clinical information
- Verify unexpected staining with other antibodies or techniques
- Be aware of variation in tumour phenotype
- Use **5A-SPIN** algorithm as a check list

