Paciente de 80 años con lesión pulmonar sugestiva de neoplasia.

Juan L. Gutiérrez Cierco, Sara Pabón Carrasco, Juan J. Ríos Martín.

U.G.C Anatomía Patológica.

Hospital Universitario Virgen Macarena. Sevilla.

No existen conflictos de intereses.

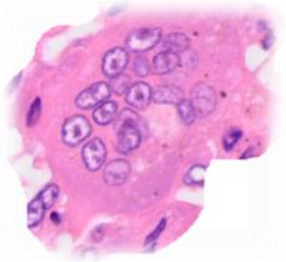

INFORMACIÓN CLÍNICA

- Hombre de 80 años, ex-fumador de 50 paquetes/año, en estudio por hemoptisis.

- En las pruebas de imagen (TAC) se identificó una masa pulmonar derecha de 8 x 5 x 5 cms **sugestiva de neoplasia broncopulmonar primaria.**

- En el PET-TAC preoperatorio no existía evidencia de enfermedad metastásica.

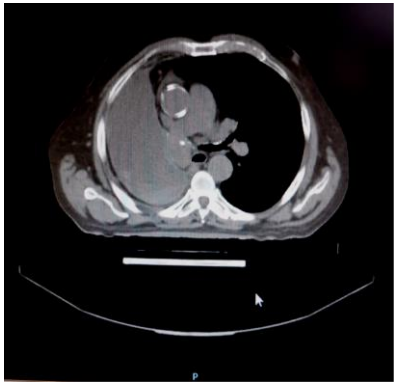

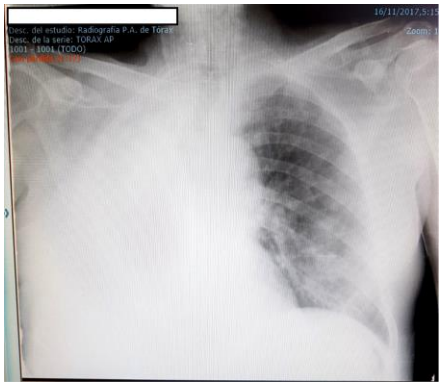

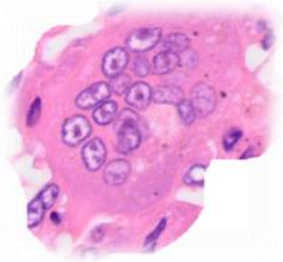

PROCEDIMIENTO

- Neumectomía derecha con linfadenectomía aortopulmonar y subcarinal con un postoperatorio favorable.

- **Hallazgo macroscópico:**

Masa multinodular de aspecto hemorrágico, de 7,6 cm, localizada principalmente en lóbulo medio, con un nódulo satélite de 1,4 cm en el mismo lóbulo.

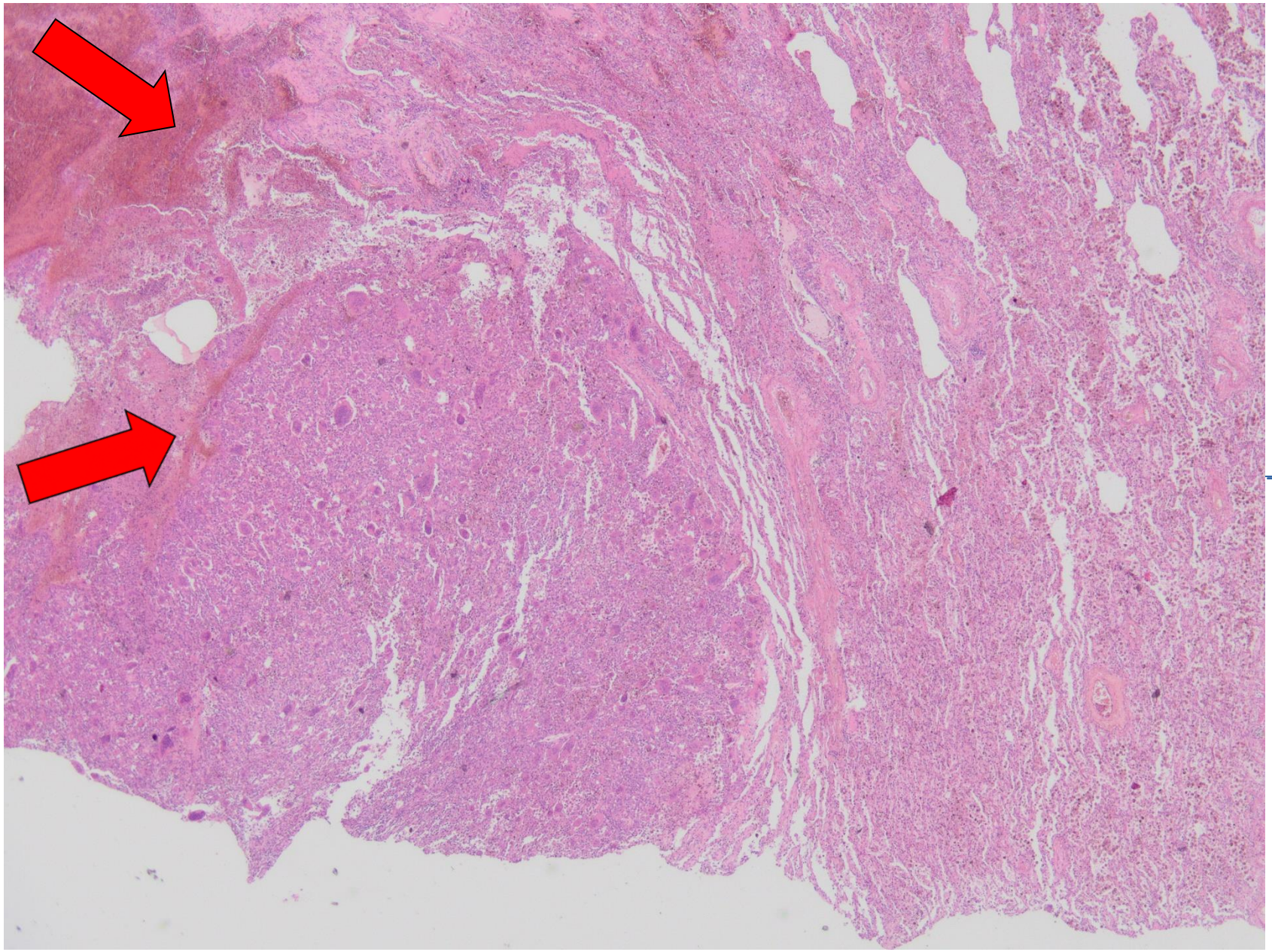

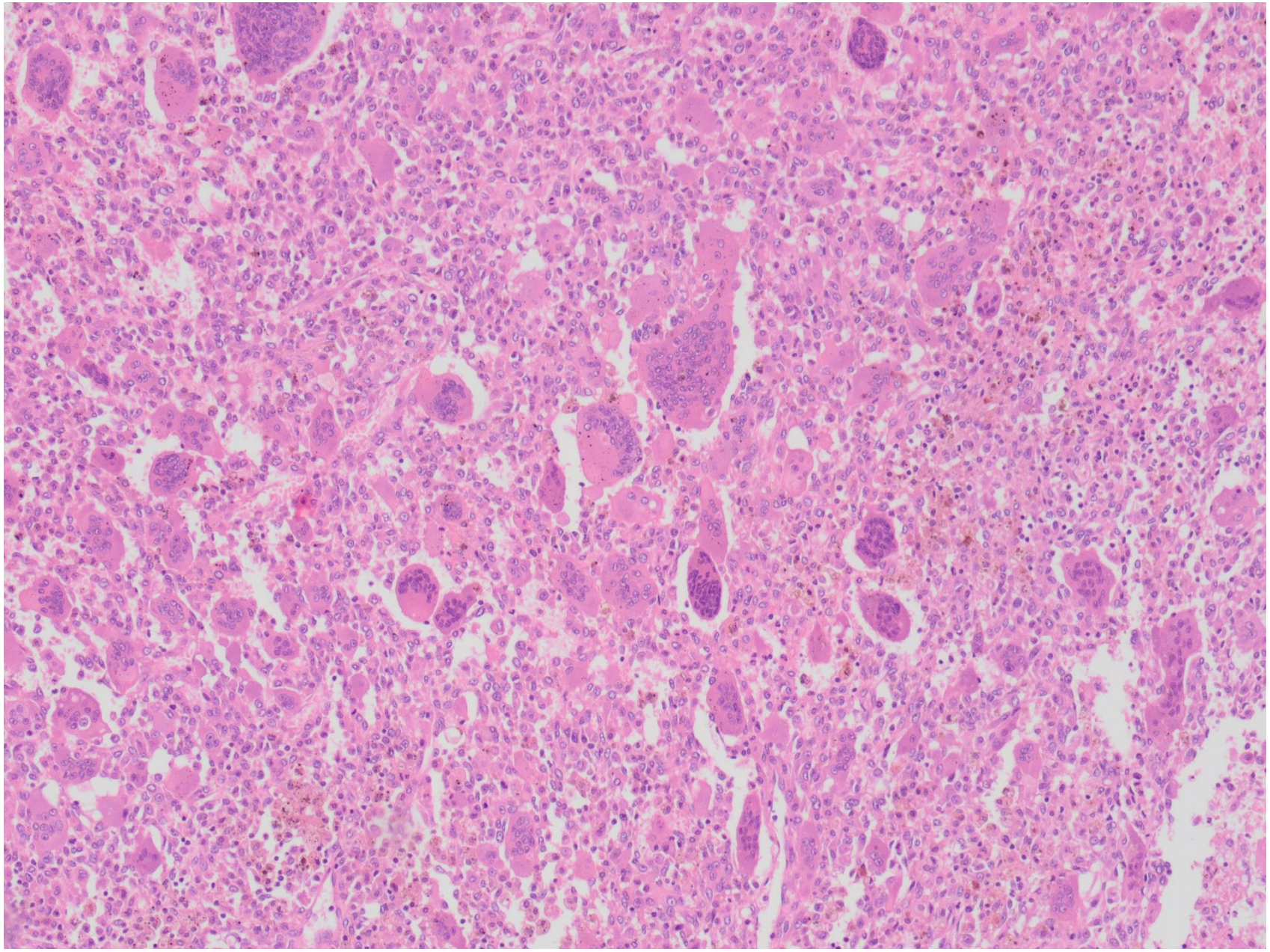

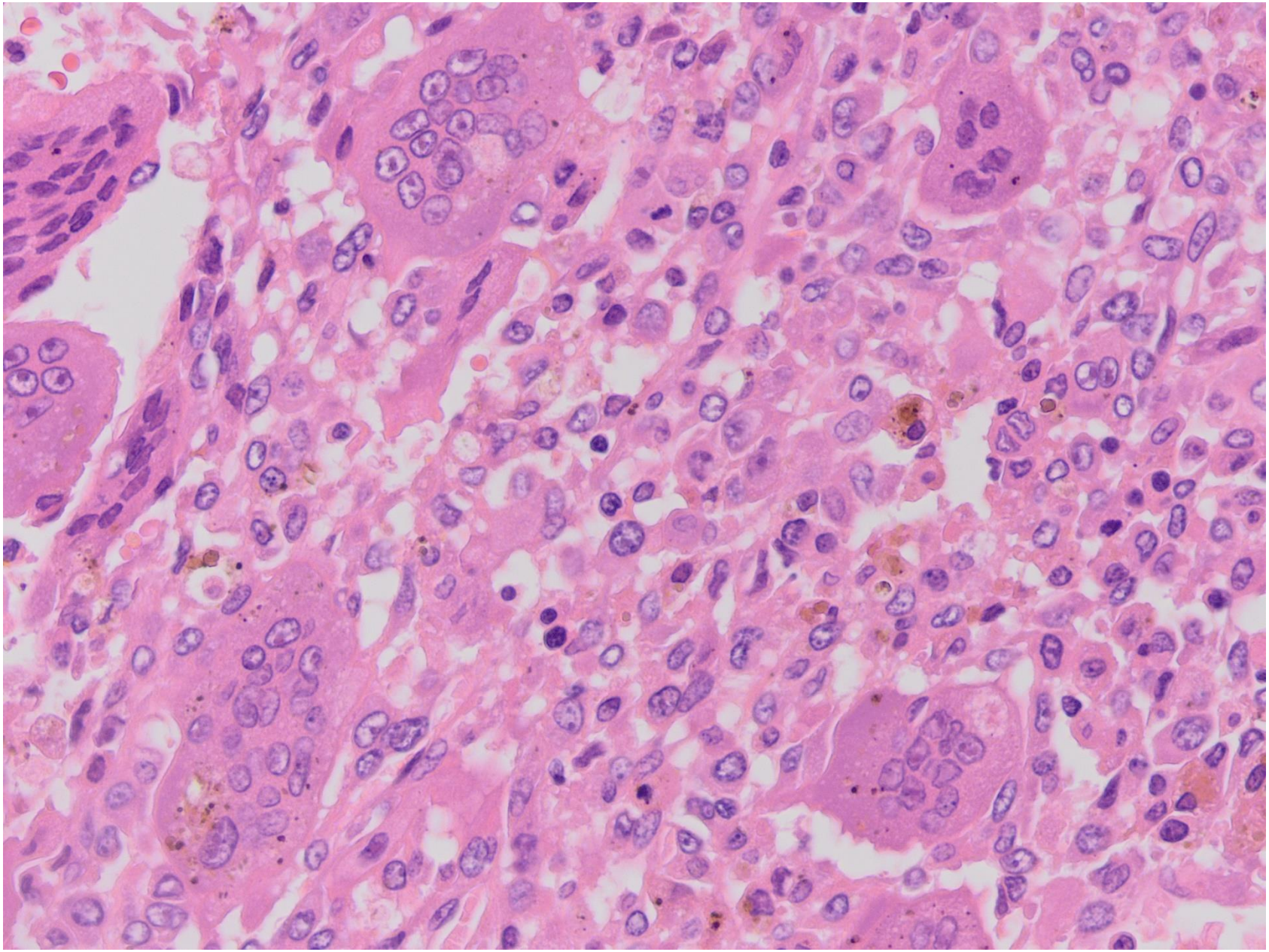

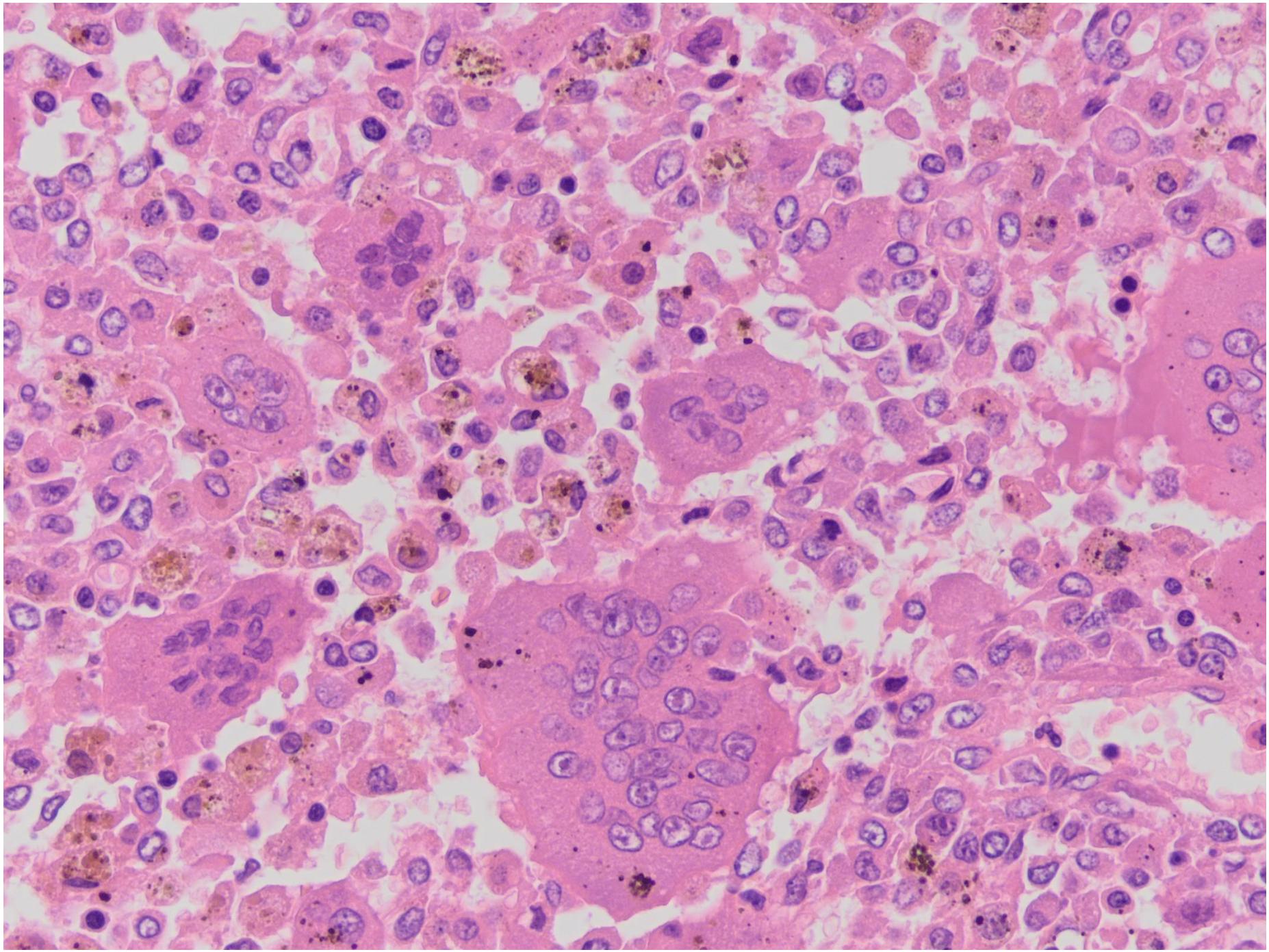

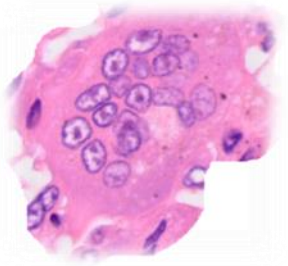

CARACTERÍSTICAS HISTOLÓGICAS

- Proliferación de **patrón sólido** con células mononucleares de tamaño medio y citoplasma eosinófilo.

- Los **núcleos eran redondos** u ovales, de cromatina finamente granular y presencia de **nucléolos pequeños sin atipia** citológica ni figuras de mitosis.

- Existían adicionalmente **numerosas células gigantes multinucleadas de tipo osteoclasto**, muchas de ellas con numerosos núcleos sin atipia ni actividad mitósica significativa.

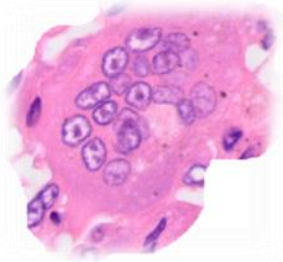

ESTUDIO ANATOMOPATOLÓGICO

- Tras un amplio muestreo de la pieza no se identificó componente de carcinoma, de sarcoma ni de otras entidades tumorales/ inflamatorias.

- Estudio inmunohistoquímico:

- Inmunorreacción positiva para CD68 y SATB2

- Negativo para amplia batería de marcadores epiteliales:

(CK7, CK20, panCK (AE1/AE3), antígeno de membrana epitelial (AME), CK34BE12).

- Otros marcadores negativos:

AML, desmina, CD34, TTF1, napsina, S100 y p40.

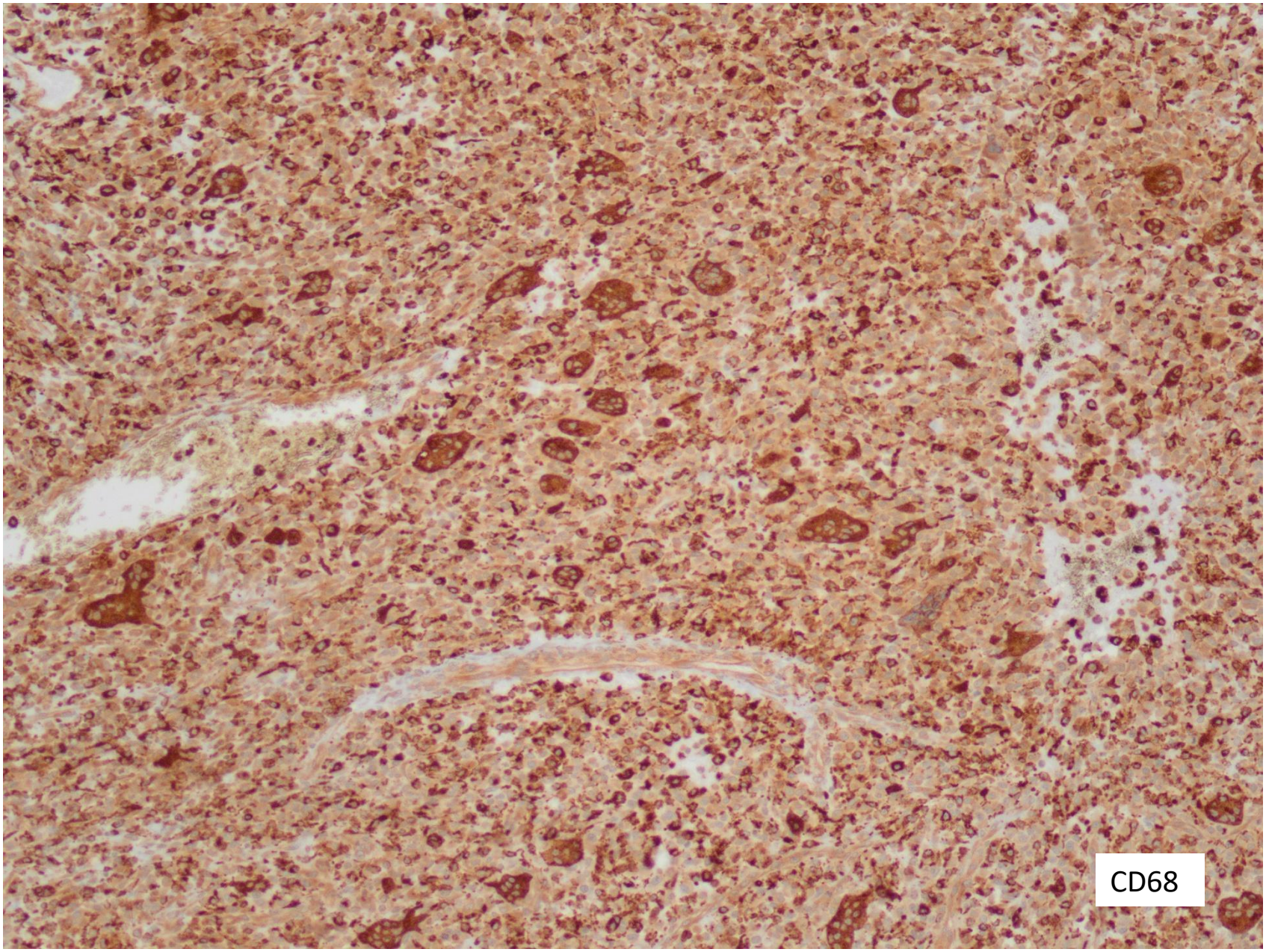
CD68

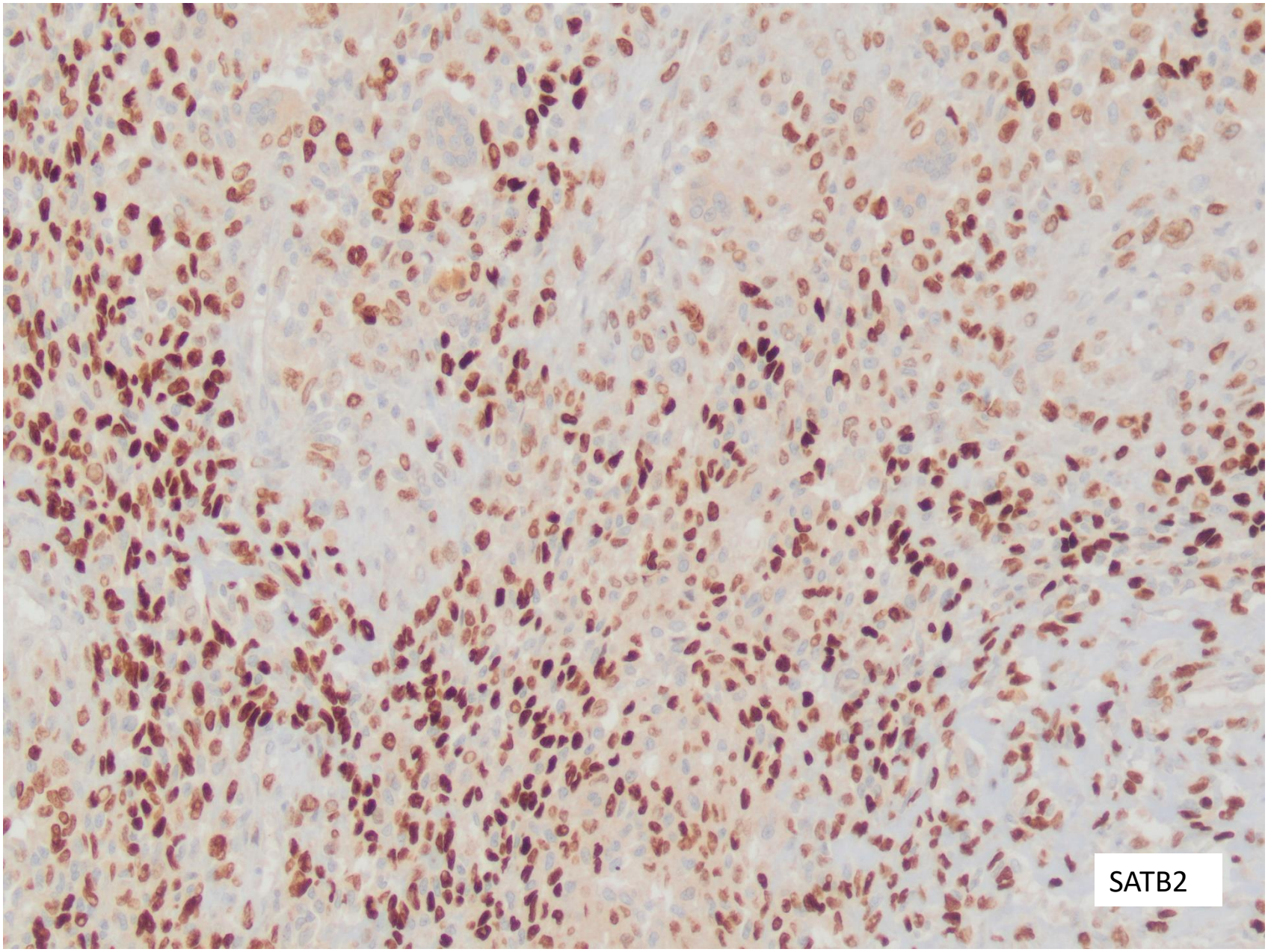
SATB2

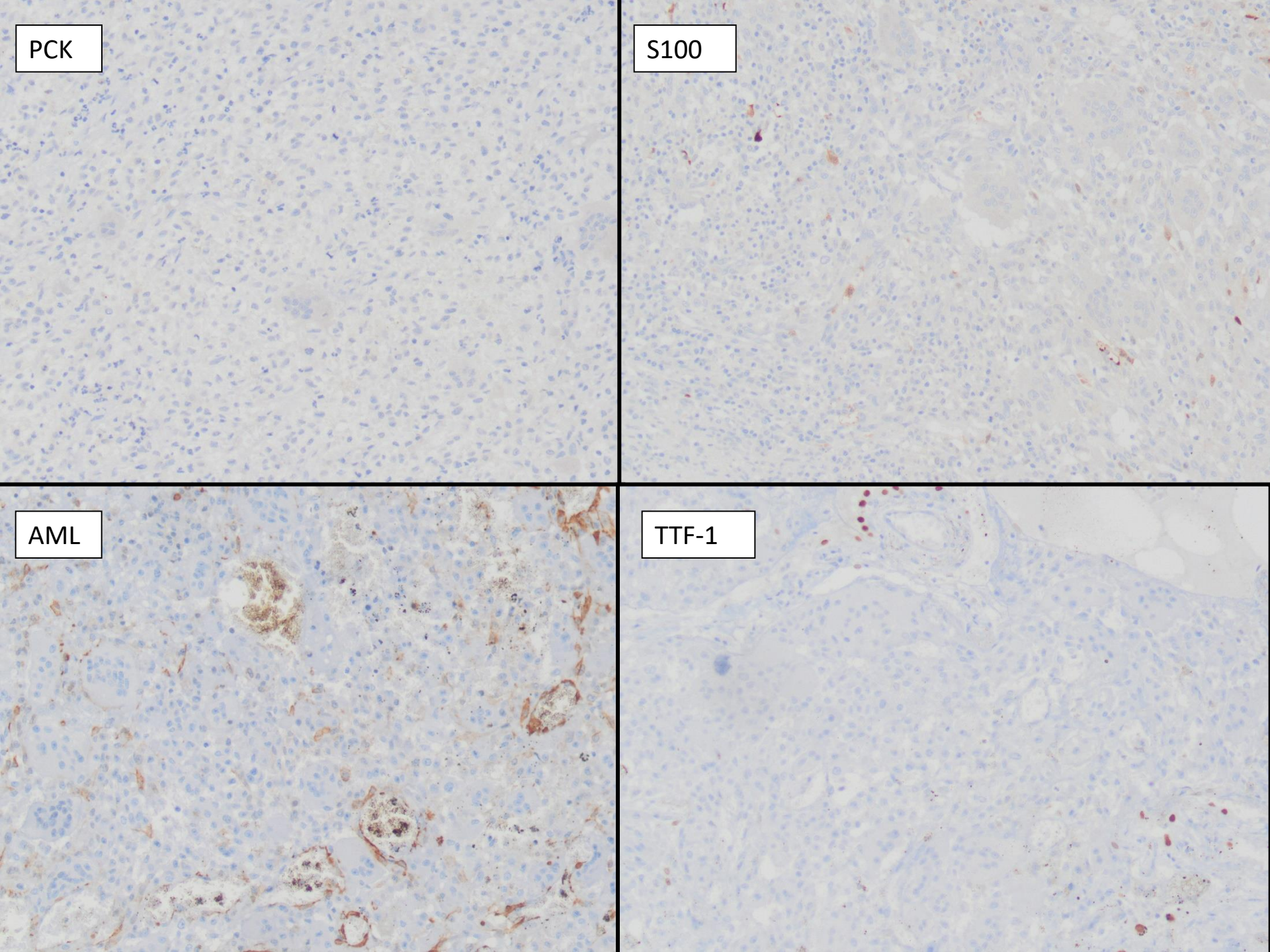
PCK
S100
AML
TTF-1

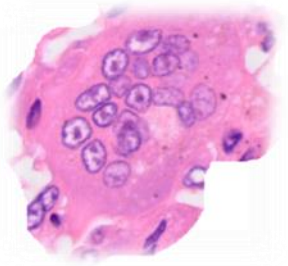

Diagnóstico Diferencial

- Tumor de células gigantes primario de pulmón

- Metástasis de un tumor de células gigantes primario óseo.

- Tumores mesenquimales o epiteliales malignos que contengan células gigantes de tipo osteoclasto.

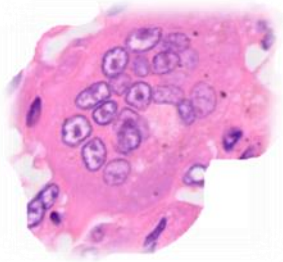

DIAGNÓSTICO

Tumor de células gigantes óseo

•Neoplasia ósea primaria benigna pero localmente agresiva compuesta por una proliferación de células mononucleares entre las que se encuentran dispersas numerosos macrófagos y células gigantes multinucleadas de tipo osteoclasto.

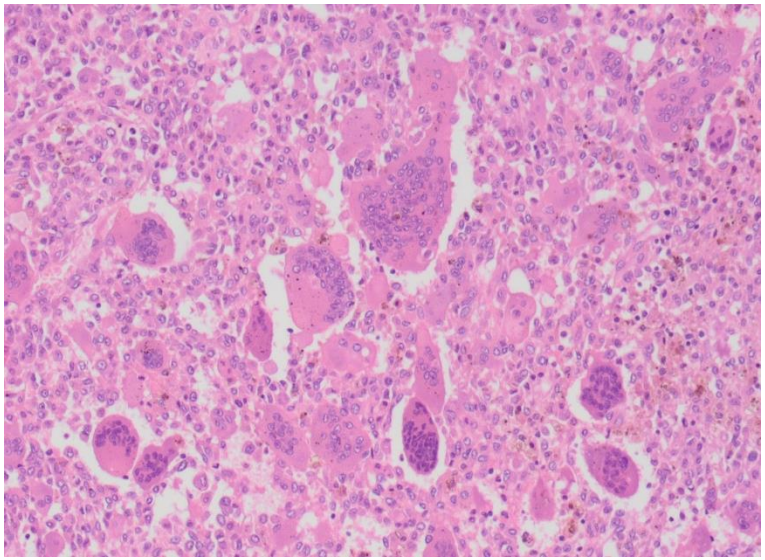

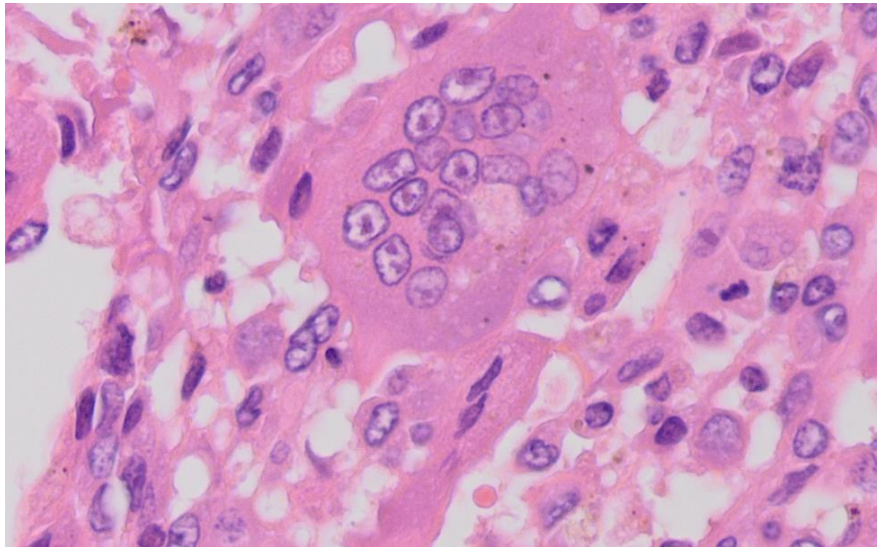

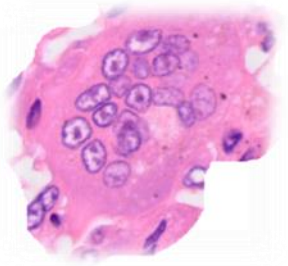

TUMOR DE CÉLULAS GIGANTES ÓSEO

- El TCG representa el 4-5% de los tumores primarios de hueso.

- El pico de incidencia se encuentra entre los 20 y los 45 años (adultos jóvenes esqueléticamente maduros), con un ligero predominio en mujeres.

- La recidiva local es frecuente pero las metástasis pulmonares se producen en el 2% de los casos.

- No existe ningún un sistema de gradación con significación pronóstica.

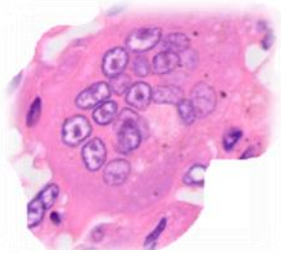

DIAGNÓSTICO

Pathology International

Pathology International 2010; **60**: 217–221 doi:10.1111/j.1440-1827.2009.02497.

Existen **formas de TCG extraóseas** con histología superponible a los TGC del hueso. En localización pulmonar estos tumores son excepcionales.

La mera presencia de células gigantes no implica el diagnóstico de TCG debido a que tumores de otro tipo también pueden presentar células gigantes de tipo osteoclasto.

Extraosseous tumors with osteoclast-like giant cells (OGC) resembling those of giant-cell tumors of the bone are rare and are found most frequently in the pancreas,[1,2] the breast,[3] and are also detected in the lungs,[4–8] the stomach,[9] the liver,[10] the thyroid gland,[11] and the urinary tract.[12] To the best of our knowledge, pleural malignant mesothelioma with OGC has not been reported to date; here we report the first such case.

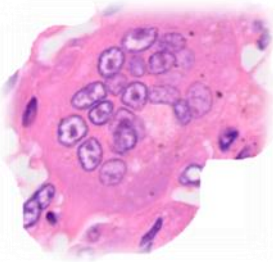

International Journal of Gynecological Pathology
34:340–350, Lippincott Williams & Wilkins, Baltimore

Original Article

Giant Cell Tumor of the Uterus: A Report of 3 Cases With a Spectrum of Morphologic Features

Jennifer A. Bennett, M.D., Sakiko Sanada, M.D., Martin K. Selig, B.A., Lida P. Hariri, M.D., Ph.D., Gunnlaugur P. Nielsen, M.D., and Esther Oliva, M.D.

Summary: Giant cell tumors, a well-recognized neoplasm of bone, can rarely be found in the uterus. Such tumors are characterized by a dual population of mononuclear and osteoclast-like giant cells that lack epithelial and specific mesenchymal differentiation. In this study, the clinicopathologic features of 3 giant cell tumors of the uterus were reviewed. Immunohistochemistry for CD68, CD163, h-caldesmon, desmin, SMA, AE1/AE3, CD10, ER, PR, cyclin D1, CD1a, CD34, CD30, S100, myogenin/myoglobin, and Ki-67 was performed in all tumors, along with ultrastructural analysis in one. The patients were 47, 57, and 59 yr and the tumors measured 2.5, 7.5, and 16.0 cm. One neoplasm was confined to the endometrium, whereas the other 2 were myometrial. All 3 tumors showed a nodular growth comprised of mononuclear and osteoclast-like giant cells. The endometrial-confined tumor consisted of histologically benign mononuclear cells, whereas the others exhibited marked atypia. Mitotic activity was up to 5/10 HPF in the benign tumor and up to 22/10 HPF in the malignant. No cytologic atypia or mitoses were observed in the giant cells. CD68 and CD10 were strongly and diffusely expressed in both components of 3 and 2 neoplasms, respectively. Cyclin D1 was focal in the mononuclear cells and focal to diffuse in the giant cells. CD163 was diffuse in the mononuclear cells, but absent to focal in the giant cells. Ultrastructural analysis lacked diagnostic features of epithelial or specific mesenchymal differentiation. Both malignant tumors demonstrated an aggressive behavior. In summary, although rare, giant cell tumor of the uterus should be included in the differential diagnosis of benign or malignant tumors containing osteoclast-like giant cells. **Key Words:** Giant cell tumor—Osteoclast-like giant cells—Uterine carcinoma and/or sarcoma.

Archivos de Bronconeumología

Manuscript Number	Title	Initial Date Submitted	Status Date	Current Status
ARBR-D-17-00758	Título: Tumor de células gigantes primario de pulmón Title: Primary pulmonary giant cell tumor of the lung	25/12/2017	27/03/2018	Aceptado / Accepted

En la revisión de la literatura que hemos realizado, tan solo hemos encontrado 6 casos en total de TCG primarios de pulmón. De ellos, tres hombres, de 63, 61 y 40, y una mujer 77 años respectivamente, de los que solo existen datos de seguimiento de uno de los pacientes que se encontraba libre de enfermedad a los 15 meses. De los otros dos casos no pudimos acceder a datos clínicos ni epidemiológicos[5-11].

Histopathology

Histopathology 2013, **63**, 36–49. DOI: 10.1111/his.12138

SATB2 is a novel marker of osteoblastic differentiation in bone and soft tissue tumours

James R Conner & Jason L Hornick
Department of Pathology, Brigham and Women's Hospital, Harvard Medical School, Boston, MA, USA

Date of submission 28 February 2013
Accepted for publication 18 March 2013
Published online *Article Accepted* 22 March 2013

Conner J R & Hornick J L
(2013) *Histopathology* **63**, 36–49
SATB2 is a novel marker of osteoblastic differentiation in bone and soft tissue tumours

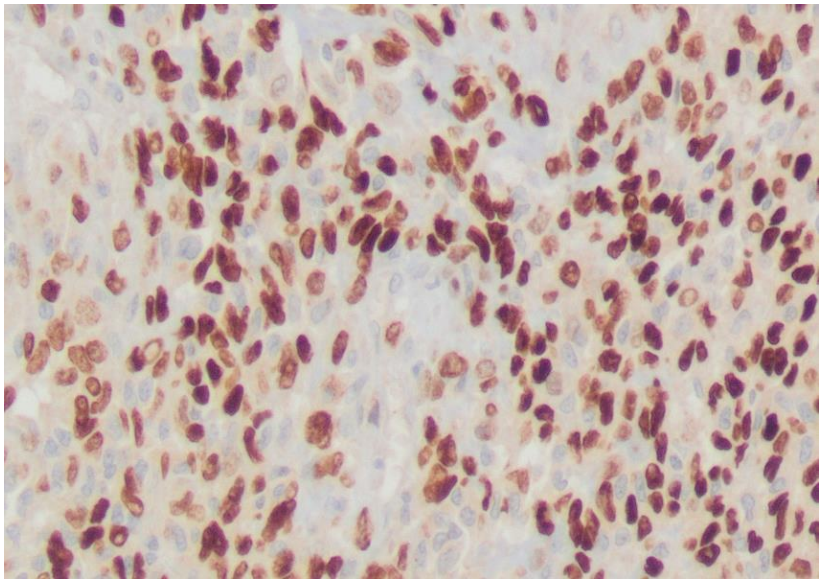

Table 1. Summary of immunohistochemical staining for SATB2 in bone and soft tissue tumours

	No. of cases	No. (%) of positive cases
Malignant bone tumours		
Osteosarcoma	43	43 (100)
Chondrosarcoma (conventional)	10	0 (0)
Dedifferentiated chondrosarcoma	11	8 (73)*
Ewing sarcoma	8	0 (0)
Plasmacytoma	8	0 (0)
Chordoma	5	0 (0)
Epithelioid haemangioendothelioma	5	0 (0)
Benign bone tumours		
Osteoblastoma	5	5 (100)
Osteoid osteoma	6	6 (100)
Giant cell tumour	6	5 (83)
Fibrous dysplasia	5	5 (100)
Aneurysmal bone cyst	5	0 (0)
Chondromyxoid fibroma	6	3 (50)
Chondroblastoma	6	4 (67)†
Soft tissue tumours		
Extraskeletal osteosarcoma	9	8 (89)
Leiomyosarcoma	5	1 (20)‡
Unclassified pleomorphic sarcoma	11	1 (9)
Dedifferentiated liposarcoma	5	5 (100)‡
Pleomorphic liposarcoma	5	0 (0)
Pleomorphic rhabdomyosarcoma	6	0 (0)
Sclerosing rhabdomyosarcoma	6	0 (0)
Epithelioid angiosarcoma	6	0 (0)
Malignant peripheral nerve sheath tumour	9	2 (22)‡
Ossifying fibromyxoid tumour	6	0 (0)
Sclerosing PEComa	5	0 (0)

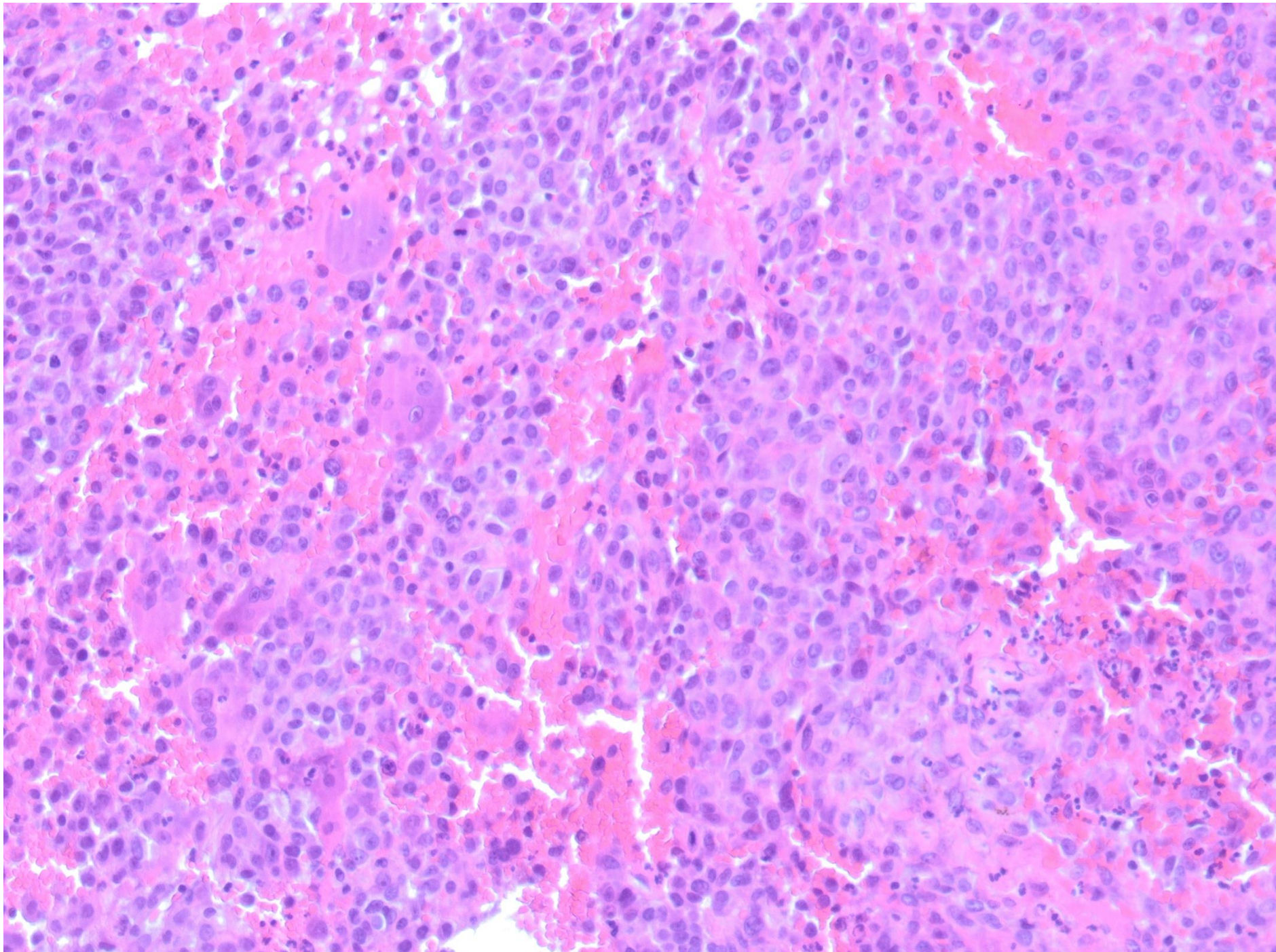

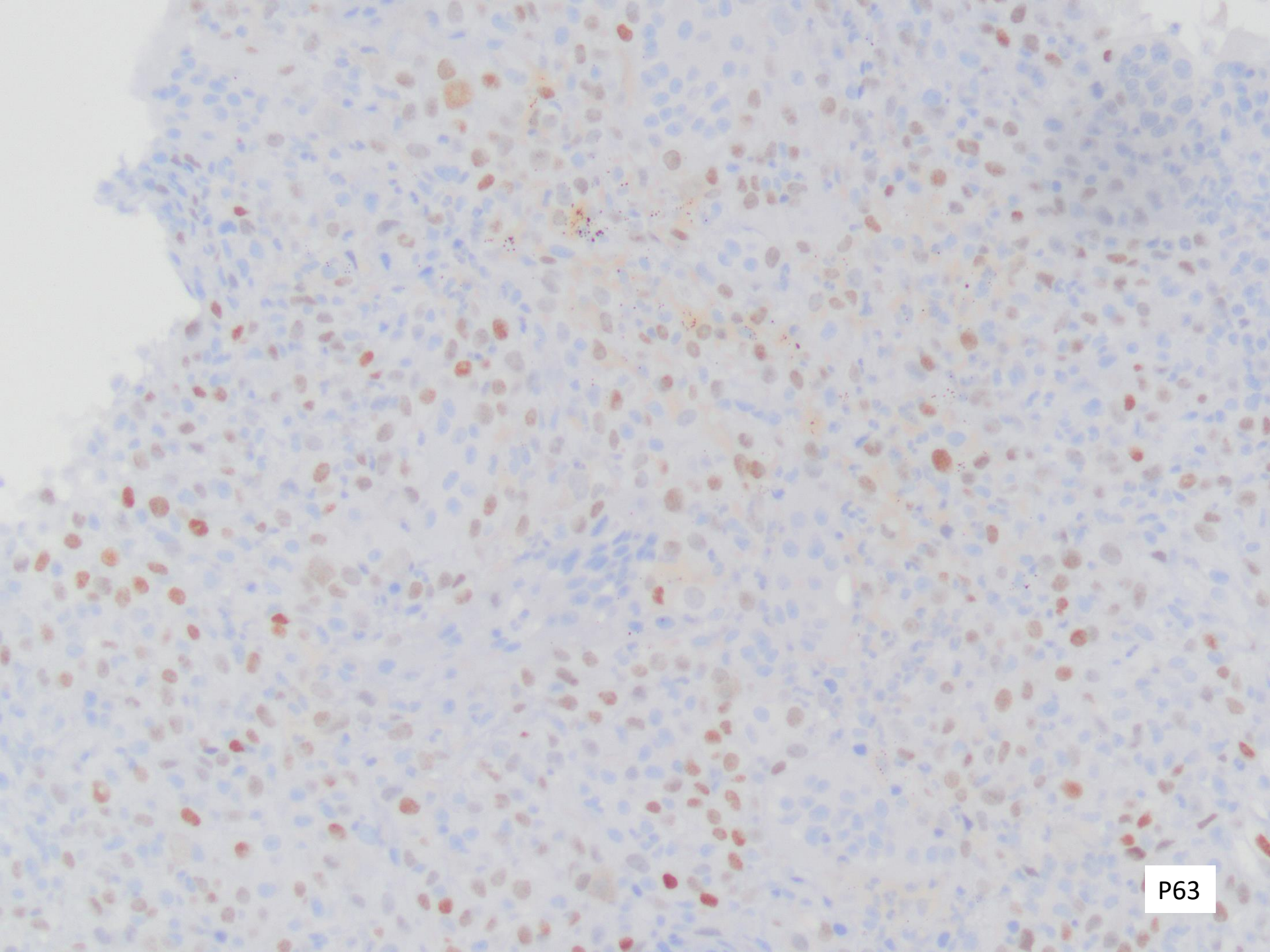
P63

Histopathology

Histopathology 2017, **71**, 453–460. DOI: 10.1111/his.13249

Phenotypic and molecular differences between giant-cell tumour of soft tissue and its bone counterpart

Irene Mancini,[1] Alberto Righi,[2] Marco Gambarotti,[2] Piero Picci,[2] Angelo P Dei Tos,[3] Steven D Billings,[4] Lisa Simi[1] & Alessandro Franchi[5]

[1]*Department of Clinical and Experimental Biomedical Sciences, University of Florence, Florence,* [2]*Department of Pathology, Rizzoli Institute, Bologna,* [3]*Department of Medicine, University of Padua School of Medicine, Padua, Italy,* [4]*Department of Pathology, Cleveland Clinic, Cleveland, OH, USA, and* [5]*Section of Anatomical Pathology, Department of Surgery and Translational Medicine, University of Florence, Florence, Italy*

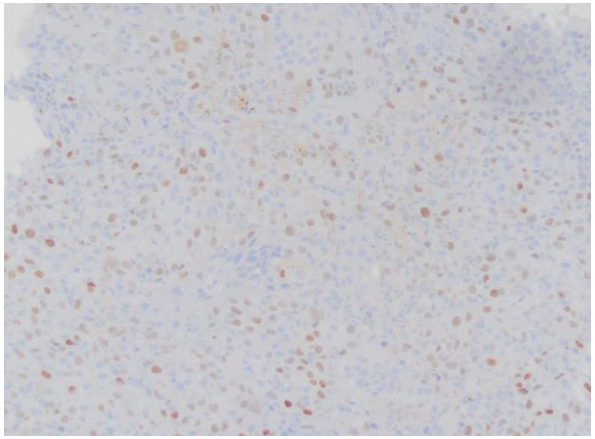

Table 3. Summary of the results of the immunohistochemical studies conducted on eight giant-cell tumours of soft tissues

	RANK		RANKL		SATB2		RUNX2		CD14		CD33		p63	
Case	MCs	GCs	MCs	GCs	MCs	GCs	MCs	GCs	MCs	GCs	MCs	GCs	MCs	GCs
1	+++	+++	–	–	–	–	+++	–	+++	–	+	+++	+	–
2	+++	+++	++	–	–	–	+++	–	+++	–	+	+++	+	–
3	++	+++	++	–	–	–	+++	–	++	–	++	+++	–	–
4	+	++	–	–	–	–	+	–	++	–	+	+++	+	–
5	++	++	–	–	–	–	+++	–	++	–	+	++	+	–
6	++	+++	–	–	++	–	+++	–	++	–	++	+++	–	–
7	++	+++	–	–	+++	–	+++	–	++	–	++	+++	+	–
8	++	++	–	–	–	–	+++	–	++	–	+	+++	–	–

GC, Osteoclast-like giant cell; MC, Mononuclear cell.
–, 0; +, 1–20%; ++, 21–50%; +++, >50%.

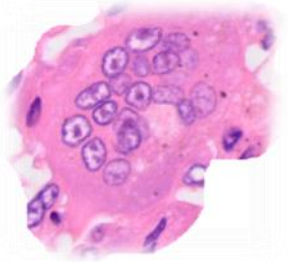

CONCLUSIONES

- Presentamos un caso muy infrecuente de neoplasia pulmonar primaria con un curso evolutivo agresivo y que plantea problemas de diagnóstico diferencial histopatológico.

- El estudio inmunohistoquímico para TCG suele ser positivo para p63 y SATB2.*

- Es necesario realizar una adecuada correlación clínica, radiológica e histológica para emitir el diagnóstico.

MUCHAS GRACIAS

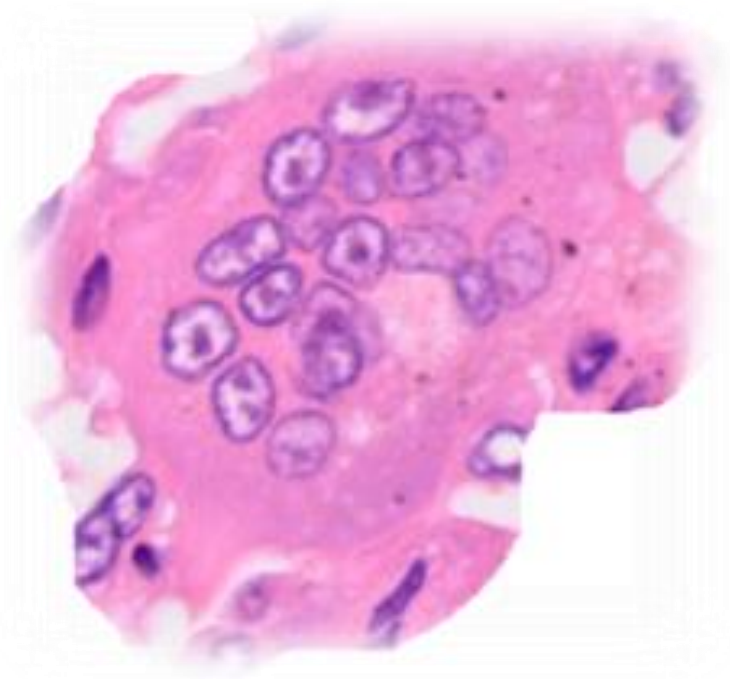

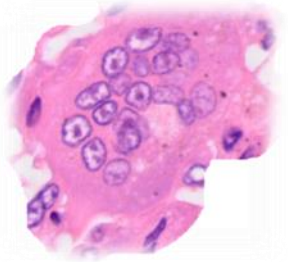

REFERENCIAS BIBLIOGRÁFICAS

1 Fletcher CDM. World Health Organization, International Agency for Research on Cancer. WHO Classification of Tumours of Soft Tissue and Bone . 4th edn. Lyon: IARC Press, 2013.

2 Itami H, Ohbayashi C, Sakai Y, Kajimoto K, Sakuma T. Pleural malignant mesothelioma with osteoclast-like giant cells. Pathol Int 2010;60:217-21. DOI: 10.1111/j.1440- 1827.2009.02497.x

3 Skubitz KM, Manivel JC. Giant cell tumor of the uterus: case report and response to chemotherapy. BMC Cancer 2007;7:46. DOI: 10.1186/1471-2407-7-46

4 Dickson BC, Li SQ, Wunder Js et al. Giant cell tumor of bone express p63. Mod Pathol 2008;21:369-75. DOI: 10.1038/modpathol.2008.29

5 Bennett JA, Sanada S, Selig MK, Hariri LP, Nielsen GP, Oliva E. Giant Cell Tumor of the Uterus: A Report of 3 Cases With a Spectrum of Morphologic Features. Int J Gynecol Pathol

2015;34:340-50. DOI: 10.1097/PGP.0000000000000164

6 Orosz Z, Tóth E, Viski A. Osteoclastoma-like Giant Cell Tumor of the Lung. Pathol Oncol Res 1996;2:84-88

7 Kuroda M, Oka T, Horiuchi H, Ishida T, Machinami R, Hebisawa A. Giant cell tumor of the lung: an autopsy case report with immunohistochemical observations. Pathol Int 1994;44:158-63

8 Hofmann D, Jander R, Filler D Osteoclastoma-like giant cell tumor of the lung.Thora